

# Diagnosis and Treatment of High-risk Pregnant Women With Cushing Syndrome Caused by Adrenal Tumor

Juping Zhao, MD, PhD, Parehe Alimu, MD, Jun Dai, MD, Jing Xie, MD, Danfeng Xu, MD, PhD, Fukang Sun, MD, PhD

Department of Urology, Shanghai JiaoTong University School of Medicine, Ruijin Hospital, Shanghai, China (all authors).

## ABSTRACT

**Introduction:** The occurrence of pregnancy with Cushing syndrome (CS) is rare but with high risks, posing a great challenge to the clinical diagnosis and treatment of the disease.

**Case Description:** From Aug 2016 to Aug 2019, we admitted two pregnant women with CS caused by adrenal tumors. After multidisciplinary consultation, they underwent emergency Cesarean section because of heart failure and severe hypoxemia, and finally delivered a living baby after adjuvant therapy. Both patients underwent retroperitoneal laparoscopic adrenalectomy (RLA) 2.6 and 1.5 months postpartum to have the adrenal tumors removed successfully. The postoperative pathology confirmed the adrenal tumor as adrenocortical adenoma. Partial hormone replacement therapy was initiated postoperatively and withdrawn uneventfully 1 year after RLA in both patients, and both patients have recovered well.

**Conclusions:** It is difficult to find CS in early pregnancy, and when it is detected in late pregnancy, it often poses a great risk because it is necessary to consider the safety of both mother and fetus, which requires multidisciplinary coordination and cooperation to positively adjust the cardiopulmonary function and internal environment after Cesarean section, knowing that timely RLA to remove the adrenocortical adenoma can effectively cure CS.

**Key Words:** Pregnancy, Cushing syndrome, Adrenal tumor, Heart failure, Hypertension.

**Citation** Zhao J, Alimu P, Dai J, Xie J, Xu D, Sun F. Diagnosis and treatment of high-risk pregnant women with cushing syndrome caused by adrenal tumor. CR<sup>SLS</sup> e2020.00079. DOI: 10.4293/CRSLS.2020.00079.

Drs. Zhao and Alimu each contributed fully and equally to this work.

**Copyright** © 2021 by SLS, Society of Laparoscopic & Robotic Surgeons. This is an open-access article distributed under the terms of the Creative Commons Attribution-Noncommercial-ShareAlike 3.0 Unported license, which permits unrestricted noncommercial use, distribution, and reproduction in any medium, provided the original author and source are credited.

**Funding:** This research was funded by National Natural Science Foundation of China Grant number 81572621.

**Competing interests:** none declare.

**Informed consent:** Dr. Fukang Sun declares that written informed consent was obtained from the patient's for publication of this study/report and any accompanying images.

**Address correspondence to:** Corresponding author: Fukang Sun, MD, PhD, Department of Urology, Shanghai JiaoTong University School of Medicine, Ruijin Hospital, Shanghai 200025, China. Telephone: +086-13301797855, E-mail: sfk10570@rjh.com.cn

## INTRODUCTION

Cushing Syndrome (CS) in women patients often leads to infertility due to ovulatory dysfunction<sup>1</sup>, and once they get pregnant, abnormal hormonal secretion during pregnancy would in turn promote the progression of CS, causing hypertensive crisis, heart failure, respiratory failure, and other severe complications that seriously endanger the life of the patients. Misdiagnosis and

delayed treatment are likely to occur because it is sometimes difficult to differentiate increased body weight and stretchmarks during pregnancy from the symptoms of CS, which poses a huge threat to the life of both mother and fetus<sup>2,3</sup>, and therefore should arouse high vigilance in clinical practice. In this article, we report two high-risk pregnant women complicated with CS who were admitted and treated in our hospital during the past four years.

## CASE REPORT

### Case 1

A 26-year-old woman underwent emergency Cesarean section at gestational age of 30 weeks in a local hospital on 08–25-2016 because of heart failure (cardiac function grade III) and pulmonary infection with hypoxemia (SpO<sub>2</sub> 80% under mask oxygen inhalation), and later was transferred to our hospital because of uncontrolled hypertension (maximum BP 170/100 mmHg). Postpartum emergency CT revealed the existence of a tumor in the left adrenal gland with the maximum diameter of 3.2 cm (Figure 1A). As a serum cortisol test revealed disappearance of circadian rhythm, the diagnosis of CS was suspected. On 11–10-2016 (2.6 months postpartum), the patient underwent retroperitoneal laparoscopic adrenalectomy (RLA) to have the left adrenal tumor removed successfully. The operation lasted 40 minutes. Postoperative pathology confirmed the diagnosis of adrenocortical adenoma. After 3-day postoperative observation, the patient was discharged from the hospital, when the serum cortisol concentration at 8:00 am decreased from preoperative 25.5  $\mu\text{g/dL}$  to 11.1  $\mu\text{g/dL}$  (reference range: 6.7–22.6  $\mu\text{g/dL}$ ); 24-hour urinary-free cortisol (UFC) decreased from preoperative 1110.7  $\mu\text{g/24 h}$  to 48.0  $\mu\text{g/24 hour}$  (reference range: 21–111  $\mu\text{g/24 hour}$ ); and serum adrenocorticotrophic hormone (ACTH) increased from preoperative 4.6 pg/mL to 34.5 pg/mL (reference range: 7–65 pg/mL). Cortisone acetate partial replacement therapy was initiated postoperatively. The dose of the hormone was tapered gradually on the outpatient basis and withdrawn completely 1 year after treatment. After adrenalectomy, BP was improved significantly and kept stable around 125/80 mmHg. In addition, the Apgar score of the baby at birth was 8-9-9, weighing 3 400 g. After 1-month hospital observation, the baby was discharged from the hospital and thereafter followed up for 3 years, showing good development and normal intelligence.

### Case 2

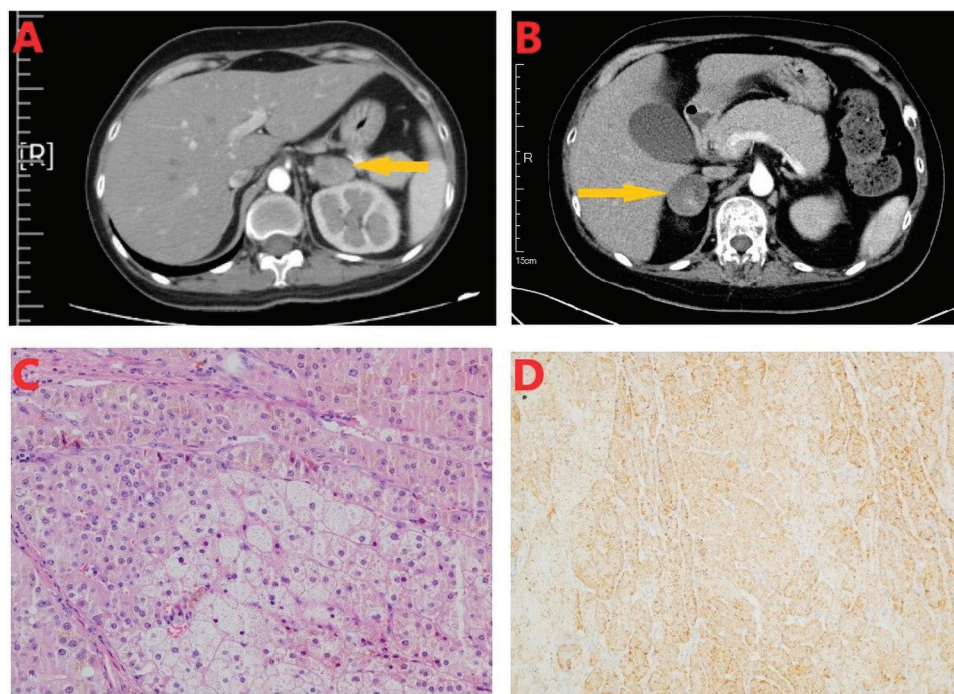
A 27-year-old woman was transferred to our hospital on 04–25-2019 at the gestational age of 29 weeks for emergency Cesarean section because of preeclampsia, cardiac dysfunction (grade III), hypamion, fetal growth retardation, and hypokalemia (2.8 mmol/L). Prepartal emergency ultrasound suggested a lesion in the right adrenal gland with the maximum diameter of 3.5 cm (Figure 1B). As a serum cortisol test revealed disappearance of circadian rhythm, the diagnosis of CS was considered. On 06–10-2019 (1.5 months postpartum), the patient underwent RLA to have the tumor in the right adrenal gland removed successfully. The operation lasted

50 minutes. Postoperative pathology confirmed the diagnosis of adrenocortical adenoma (Figure 1C,D). After 3 days postoperative observation, the patient was discharged from the hospital, when the serum cortisol concentration at 8:00 am decreased from preoperative 35.3  $\mu\text{g/dL}$  to 18.4  $\mu\text{g/dL}$  (reference range: 6.7–22.6  $\mu\text{g/dL}$ ); 24-hour UFC superlinearly decreased to 69.2  $\mu\text{g/24 hour}$  (reference range: 21–111  $\mu\text{g/24 hour}$ ); and serum ACTH increased from preoperative 2.3 pg/mL to 5.3 pg/mL (reference range: 7–65 pg/mL). Cortisone acetate replacement therapy was initiated postoperatively, and the oral hormone was withdrawn completely in 1 year. Postoperative BP was improved significantly and stabilized around 130/90 mmHg. Apgar score of the baby at birth was 5-6-6, weighing 990 g, which increased to 2000 g after 2 months hospital observation and the baby finally survived, with good development and normal intelligence during the 1-year follow-up period.

## DISCUSSION

### Risks of Pregnancy Complicated by CS

There is a very low occurrence of pregnancy complicated by CS, and only about 300 cases have been reported worldwide in the literature<sup>3,4</sup>. About 85% of women with CS had ovulatory dysfunction, leading to infertility because of feedback inhibition of the hypothalamus-pituitary-ovary axis due to secretion of large amounts of cortisol hormone<sup>5</sup>. Misdiagnosis and delayed treatment are likely to occur because increased body weight and stretchmarks during pregnancy are quite similar to the clinical symptoms of CS. It was, respectively, in gestational age of 30 and 29 weeks that the two patients in our series were found to have CS caused by adrenal tumors, and both patients were transferred from two lower-level district hospitals to our institution as emergency cases, probably because district hospitals had limited ability to deal with such conditions. Pregnancy with CS would undoubtedly increase the occurrence of adverse events in both the pregnant woman and the baby. Caimari et al<sup>4</sup> summarized 263 cases of pregnancy-complicated CS reported between 1952 and 2015, and found that the occurrence of hypertension, eclampsia, and diabetes was 41%, 26%, and 37%, respectively. In addition, the occurrence of premature birth was 43%, the fetal death rate was 24%, and the fetal growth retardation rate was 21%. For these reasons, particular attention should be paid to pregnancy-complicated CS by giving a comprehensive consideration to concrete conditions of both the mother and



**Figure 1.** (A) Enhanced computed tomography (CT) scan demonstrated a mass (*arrow*) in the left adrenal gland with maximum diameter of 3.2 cm in a 26-year-old woman (case 1). (B) Enhanced CT scan demonstrated a mass (*arrow*) in the right adrenal gland with maximum diameter of 3.5 cm in a 27-year-old woman (case 2). (C) Hematoxylin and eosin staining ( $\times 100$ ). (D) Immunohistochemical examination ( $\times 100$ ) indicated Melan-A(+).

baby and implementing the clinical diagnosis and treatment through multidisciplinary team cooperation.

### Diagnosis of Pregnancy Complicated by CS

Some clinical manifestations of CS during pregnancy are quite similar to those of normal pregnancy, such as obesity, stretchmarks, lower extremity edema, and abnormal glucose tolerance, which are likely to be confused with pregnancy-induced hypertension or diabetes. The diagnosis of CS should be considered when the triad of hypertension, skin ecchymosis, and muscular atrophy appears<sup>4,6</sup>. In our opinion, “buffalo hump”, dorsal fat pad, is the most remarkable sign that can be differentiate CS from normal pregnancy because it cannot appear in average pregnant women. In our two cases, buffalo hump was seen as an important sign of CS. Considering the potential harm of CT radiation to the fetus, ultrasonography is the preferred location examination<sup>7</sup>, and it can be performed at any stage of pregnancy. We recommend bilateral adrenal ultrasonography as a routine examination during pregnancy. Magnetic resonance (MR) is an alternative imaging examination for the diagnosis of pituitary adenoma and space-occupying lesions in

the adrenal gland. It is reported that MR is potentially teratogenic to the fetus in the early pregnancy stage before 12 weeks of gestation and therefore should be used discreetly, considered safe after 32 weeks of gestation, and should weight the benefit and risk during the other pregnancy stages and be selected with caution after full communication between the doctor and the patient<sup>8</sup>. In our two patients, we used ultrasonography for antenatal examination and CT only for postpartum location examination.

As for endocrine evaluation, pregnant women with CS show disappearance of the plasma cortisol circadian rhythm, however, the plasma cortisol circadian rhythm remains there in normal pregnant women. During pregnancy, the placenta secretes ACTH and therefore the serum ACTH level will be elevated, whereas it is decreased in pregnant women with CS<sup>8,9</sup>. 24-hour UFC will also be elevated probably due to ACTH secreted by the placenta. However, 24-hour UFC usually does not exceed 3-fold of the upper limit of the normal range during the middle and late pregnancy stages; in case it exceeds 3-fold of the upper limit, CS should be suspected<sup>8</sup>. Large- and small-dose dexamethasone inhibition tests can be used to confirm the diagnosis,

but there are controversies over the time selection of the test<sup>10</sup>. Given the potential adverse effects on the fetus, we do not recommend the use of the test before birth; if the general condition of the patient permits and upon informed consent from the patient, it can be considered after birth. We did not do this test in our two patients due to the consideration of the negative impact of the hormone on heart failure and possible unexpected events during the period of antiheart failure therapy.

### Timing of Operation and Preoperative Preparation for Adrenal Tumor Resection

Timing of the operation for Cushing syndrome-related adrenal tumor depends on the comprehensive analysis of the specific situation during pregnancy and individualized conditions of both the mother and fetus. According to Wu et al<sup>11</sup>, the operation can be considered during the early pregnant stage, before 12 weeks of gestation after pregnancy termination, performed during pregnancy in the middle pregnant stage between 12 and 28 weeks of gestation, and after delivery during the late pregnant stage after 28 weeks of gestation.

For pregnant women with CS in the late pregnant stage, positive measures should be taken during the period from the date of delivery to the date of operation to improve functions of the systemic organs and stabilize the internal environment.

1. Adjustment of the cardiac function: the heart function would decrease or even heart failure would occur in severe cases due to long-term hypertension, water-sodium retention, and their exacerbation during pregnancy. The two patients in our series had presented symptoms of left heart failure such as inability to lie flat, and therefore we closely monitored the parameters of echocardiography, myocardial zymograms, and brain natriuretic peptide before adrenal surgery.
2. Adjustment of the pulmonary function: CS can be associated with pneumonia and pleural effusion, and therefore anti-infection therapy should be arranged positively postpartum to improve the pulmonary function.
3. Control of hypertension: combined use of different types of antihypertensive drugs is advocated to control BP below the target BP of 160/100 mmHg.
4. Adjustment of electrolytes: patients with CS are often associated with hypokalemia. In addition to potassium supplements, an appropriate amount of spironolactone can also be used, knowing that it

cannot only control blood potassium but water-sodium retention due to its diuretic effect. The target blood potassium level should be controlled above 3.0 mmol/L.

Sakota et al<sup>2</sup> reported a case of CS in a 35-year-old high-risk pregnant woman, who underwent emergency Cesarean section at the gestational age of 35<sup>+3</sup> weeks because of congestive heart failure and hypoxemia. The patient was transferred to the intensive care unit (ICU) to have heart function and electrolyte disturbance corrected after delivery, and underwent RLA 32 days postpartum. Both blood and urine cortisol levels quickly returned to normal ranges after surgery. The two patients in our series underwent RLA 2.6 and 1.5 months postpartum, respectively.

RLA via the posterior approach is the preferred choice for removing the adrenal tumor, because it can avoid interference of the abdominal organs and help recover gastrointestinal function and ambulation quickly. We used posterior RLA in both patients and successfully completed the operation within 1 hour. As we found during the operation, there is much adipose tissue and abundant tumor nourishing vessels, and therefore a casual touch may cause bleeding. For this reason, we suggest that the procedure should be performed according to the “three-layer” theory via the posterior approach as described by Zhang et al<sup>12</sup> in that it can help find the tumor and have it resected quickly and accurately. In our center, RLA was performed by using 3 ports lateral retroperitoneal approach. The first dissection plane was between the perirenal fat and anterior renal fascia located at the superomedial side of the kidney, and when entering this plane, the adrenal gland could be identified on the whole. The following dissections proceeded in the second plane between the posterior renal fascia and the lateral aspect of perirenal fat. Then, the third plane was located on the parenchymal surface of the upper renal pole. The adrenal central vein was dealt with at the final stage.

### Hormone Replacement Therapy after Adrenalectomy

Glucocorticoid partial replacement therapy is necessary after adrenalectomy to avoid the occurrence of adrenal crisis. Compared with ordinary CS, there is no evidence-based consent guideline on the dosage and duration of hormone supplementation after adrenalectomy<sup>13</sup>. According to our experience and practice, the hormone dosage can depend on the plasma cortisol concentration at 8:00 am and 24-hour UFC on day 1 postoperation. Generally speaking, we advocate intravenous dripping of 150–200 mg of hydrocortisone



on day 1 postoperation and 50–75 mg of hydrocortisone on day 2 postoperation, and oral administration of 37.5 mg of cortisone acetate hydrocortisone from day 3 for 1 month maintenance treatment, and then the oral dose should be adjusted according to the plasma cortisol concentration at 8:00 am and 24-hour UFC thereafter. The dose-tapering amplitude should be smaller and slower as compared with that in ordinary CS cases, and complete withdrawal may need a year or so. In our two cases, hormone therapy was discontinued completely in 1 year.

In summary, the occurrence of pregnancy complicated by CS is relatively low and therefore misdiagnosis is likely to occur, which may seriously endanger the health of both mother and baby. Clinically, it is manifested as the “triad” of hypertension, skin ecchymosis, and muscular atrophy, and “buffalo hump” is one of the most remarkable signs for differentiation diagnosis. B-type ultrasonography, MRI, and CT can be used as an auxiliary means of location diagnosis, and disappearance of the plasma cortisol circadian rhythm and abnormal elevation of 24-hour UFC (>3-fold of the upper limit of the normal range) can be used for qualitative diagnosis. Surgical treatment of adrenal tumors in pregnant women with CS should depend on specific conditions of the mother and the fetus. Posterior RLA is the surgical treatment of choice. Multidisciplinary coordination and cooperation is the guarantee of successful treatment. As there are not many cases reported in the literature, the pathogenesis, diagnosis, and treatment of the disease require further exploration.

## References:

1. Machado MC, Fragoso M, Bronstein MD. Pregnancy in patients with Cushing's syndrome. *Endocrinol Metab Clin North Am*. 2018;47(2):441–449.
2. Sakota M, Tatebe S, Sugimura K, et al. Successful management of acute congestive heart failure by emergent Caesarean section followed by adrenalectomy in a pregnant woman with Cushing's syndrome-induced cardiomyopathy. *Intern Med*. 2019;58(19):2819–2824.
3. Ildefonso-Najarro SP, Plasencia-Dueñas EA, Benites-Moya CJ, et al. Pregnancy during the course of Cushing's syndrome: a case report and literature review. *Endocrinol Diabetes Metab Case Rep*. 2020;Apr 12;2020:20–0022.
4. Caimari F, Valassi E, Garbayo P, et al. Cushing's syndrome and pregnancy outcomes: a systematic review of published cases. *Endocrine*. 2017;55(2):555–563.
5. Sharma ST, Nieman LK, Feelders RA. Cushing's syndrome: epidemiology and developments in disease management. *Clin Epidemiol*. 2015;7:281–293.
6. Darocas M, Ruiz N, Bergoglio MT, et al. A decision dilemma: Cushing syndrome during pregnancy. *J Obstet Gynaecol*. 2015;35(1):93–94.
7. Kamoun M, Mnif MF, Charfi N, et al. Adrenal diseases during pregnancy: pathophysiology, diagnosis and management strategies. *Am J Med Sci*. 2014;347(1):64–73.
8. Lindsay JR, Nieman LK. The hypothalamic-pituitary-adrenal axis in pregnancy: challenges in disease detection and treatment. *Endocr Rev*. 2005;26(6):775–799.
9. St-Jean M, MacKenzie-Feder J, Bourdeau I, et al. Exacerbation of Cushing's syndrome during pregnancy: stimulation of a cortisol-secreting adrenocortical adenoma by ACTH originating from the foeto-placental unit. *Endocrinol Diabetes Metab Case Rep*. 2019;Feb 7;2019:18–0115:17.
10. Dong D, Li H, Xiao H. The diagnosis and management of Cushing syndrome during pregnancy. *J Obstet Gynaecol*. 2015;35(1):94–96.
11. Lu Z, Luo B, Yuan Y, et al. Retroperitoneal laparoscopic resection of adrenal tumor in pregnant woman with Cushing's syndrome. *Gynecol Endocrinol*. 2020;36(5):465–468.
12. Zhang X, Fu B, Lang B, et al. Technique of anatomical retroperitoneoscopic adrenalectomy with report of 800 cases. *J Urol*. 2007;177(4):1254–1257.
13. Sammour RN, Saiegh L, Matter I, et al. Adrenalectomy for adrenocortical adenoma causing Cushing's syndrome in pregnancy: a case report and review of literature. *Eur J Obstet Gynecol Reprod Biol*. 2012;165(1):1–7.