

# Endoscopic Drainage of a Symptomatic Intraperitoneal Hematoma with a Metal Stent and Intracavitary Thrombolytics

Sarah Olivier-Cabrera, MD, Virendra Tewari, MD, Lakshmi A. Gollapudi, MD,  
Gustavo Stringel, MD, MBA

Department of Medicine, Division of Gastroenterology and Hepatobiliary Diseases, New York Medical College,  
Westchester Medical Center, Valhalla, New York (Drs. Olivier-Cabrera, Tewari, Gollapudi).

Department of Surgery, Division of Pediatric Surgery, New York Medical College, Westchester Medical Center, Valhalla,  
New York (Dr. Stringel).

## ABSTRACT

**Introduction:** Symptomatic intraperitoneal collections in difficult anatomical locations can present a management challenge. Even after access and drainage are accomplished, reaccumulation of thick material inside the cavity can continue to cause problems. The use of fibrinolytic agents has been reported to facilitate drainage of thick material, hematomas, purulence, and fibrin.

**Case Description:** We present a 16-year-old male with idiopathic thrombocytopenic purpura who developed a symptomatic intraperitoneal hematoma with dimensions of 5 × 6 × 6.7 cm, abutting the spleen, pancreas, and left kidney, caused by blunt trauma. Interventional radiology could not drain the cyst because of the location. Initial drainage was done with endoscopic ultrasound (EUS)-guided placement of a lumen apposing self-expandable 1.5 cm wide metal stent designed for cystogastrostomy. The patient continued to be febrile despite saline irrigation used in the initial procedure. Two endoscopic sessions employing thrombolytic agents (4 mg of tissue plasminogen activator and 5 mg of deoxyribonuclease) instillation into the collection at weekly intervals were used. The stent was removed after 8 weeks with complete resolution of the collection. He was discharged home and remained asymptomatic after 1 year of follow-up.

**Conclusion:** The present case demonstrates the successful and safe use of EUS-guided transgastric drainage in conjunction with fibrinolytic/thrombolytic agents to facilitate dissolution of thickened internal debris, especially in collections with a capsule when mechanical debridement can lead to spillage of infected material and cause generalized peritonitis. To the best of our knowledge, this is the first report of endoscopic drainage utilizing thrombolytic agents.

**Key Words:** Endoscopic drainage; Intraperitoneal hematoma; Transgastric drainage; Fibrinolytic agents; Thrombolytic agents.

**Citation** Olivier-Cabrera S, Tewari V, Gollapudi L, Stringel G. Endoscopic drainage of a symptomatic intraperitoneal hematoma with a metal stent and intracavitary thrombolytics. CRSLS e2020.00055. DOI: 10.4293/JSLS.2020.00055.

**Copyright** © 2020 by SLS, Society of Laparoscopic & Robotic Surgeons. This is an open-access article distributed under the terms of the Creative Commons Attribution-Noncommercial-ShareAlike 3.0 Unported license, which permits unrestricted noncommercial use, distribution, and reproduction in any medium, provided the original author and source are credited.

Disclosure: none.

Funding/Financial support: none.

Conflicts of interest: The authors declare no conflict of interest.

Informed consent: Dr. Olivier-Cabrera declares that written informed consent was obtained from the patient/s for publication of this study/report and any accompanying images.

Address correspondence to: Sarah Olivier-Cabrera, MD, Department of Medicine, Division of Gastroenterology and Hepatobiliary Diseases, New York Medical College, Westchester Medical Center, Valhalla, NY 10595, USA. Telephone: 914-297-0472; Fax: 914-493-1652, E-mail: sarah.oliviercabrera@wmchealth.org

## INTRODUCTION

Intraperitoneal collections traditionally have been treated with either radiology-guided percutaneous drainage or surgical drainage. With the advent of lumen apposing self-expandable metal stents, endoscopic ultrasound (EUS)-guided drainage has become a very efficient alternative. While fibrinolytic instillation to dissolve thick debris in large body cavities<sup>1</sup> (intrathoracic and intraperitoneal) has been used in both radiology-guided and surgical drainage, it has not been employed in endoscopy-assisted drainage.

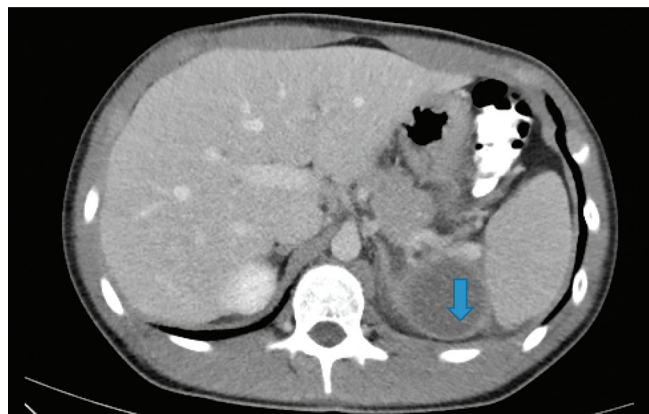## CASE REPORT

A 16-year-old male with history of idiopathic thrombocytopenic purpura, anxiety, and substance use (cannabis, pregabalin, hydrocodone, and alcohol) presented with 4 days of left upper quadrant (LUQ) abdominal pain radiating to his back. He reported abdominal trauma around 2 months previously when he fell on a shopping cart and hit his upper abdomen.

Physical examination was positive for moderate tenderness to palpation on LUQ. Laboratory test on admission were normal. Abdominal ultrasound was deemed normal. Esophagogastroduodenoscopy (EGD) and colonoscopy performed by a pediatric gastroenterologist were positive only for mild erosive gastritis. He underwent magnetic resonance enterography and contrast computer tomography (CT) scan of the abdomen and pelvis. Both studies demonstrated a 5 × 5 × 6.7 cm size, well-circumscribed cystic intraperitoneal mass, a possible hematoma, abutting the spleen, pancreas, and left kidney.

Two weeks into hospitalization, the patient developed a fever, leukocytosis, and increasing abdominal pain. He was unable to tolerate oral feedings. Blood cultures were negative. Initially, interventional radiology was consulted for percutaneous drainage. The cyst was difficult to drain percutaneously because of its location and was partially surrounded by the peritoneal space. The interventional radiologist was concerned about contamination of the peritoneal cavity with infected cyst contents (**Figure 1**).

The care team performed EGD/EUS-guided gastrostomy on a cyst using a fully covered lumen apposing self-expanding metal stent (LASEMS; Boston Scientific AXIOS stent; 1.5 cm width) (**Figure 2**). A moderate amount of purulent discharge was retrieved. After collecting a specimen for culture sensitivity, a thorough saline irrigation with 1 L of normal saline mixed with gentamicin was performed. Despite adequate antimicrobials based on results of culture and sensitivity of the aspirate from the collection (positive for *C. albicans*), the patient continued to



**Figure 1.** Initial contrast CT abdomen pelvis; arrow showing well-circumscribed intraperitoneal collection.

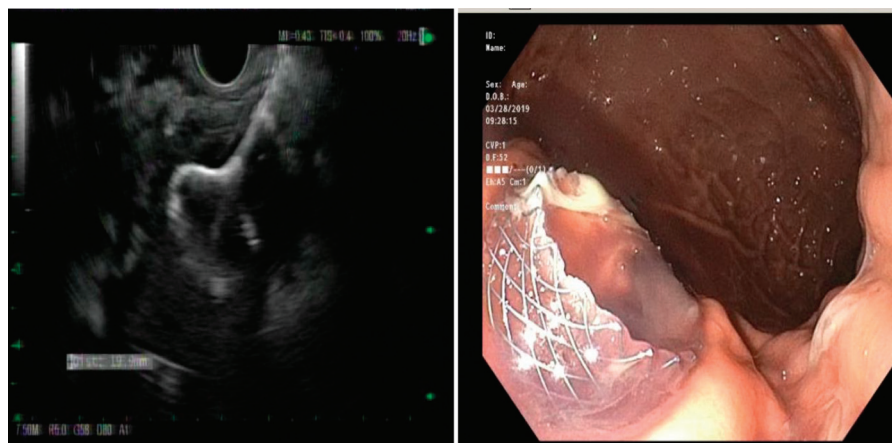
have fever, and the collection size remained unchanged on subsequent imaging.

An endoscopic lavage was repeated with 1 L of normal saline 1 week after the initial drainage. Mechanical debridement was attempted but deemed unsafe because of thick debris and uncertainty of the capsule thickness. Instead, we proceeded to instill 40 cc of saline mixed with 4 mg of tissue plasminogen activator (tPA; alteplase) using occlusion technique with a 15 mm biliary balloon for 10 min. After 1 week, another irrigation with 400 mL normal saline followed by instillation of a combination of 4 mg of tPA and 5 mg of deoxyribonuclease (DNase) into the cavity was performed using the same occlusion technique (**Figure 3**). The patient's pain and fever resolved. He was discharged and followed as an outpatient with imaging monitoring of the cavity size. At 8 weeks from the first procedure, the cavity appeared completely collapsed, and the stent was removed (**Figure 4**). He remained asymptomatic after 1 year of follow-up.

We did not consider interventional radiology drainage as endoscopic access was a more direct approach with a 1.5 cm size drain. Among all of the surgical options, this was a minimally invasive novel approach. Laparoscopic or open surgery were fall back options in case this approach failed. In addition, if we had employed thrombolytics in the first endoscopy, next two endoscopies might not have been needed.

## DISCUSSION

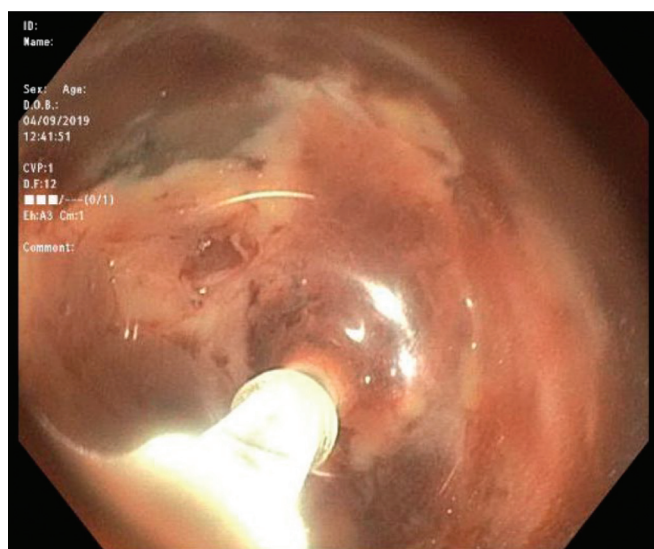
Intraperitoneal collections are defined as collections of fluid usually due to a localized infection or injury inside the peritoneal and abdominal cavity. They can involve any organ



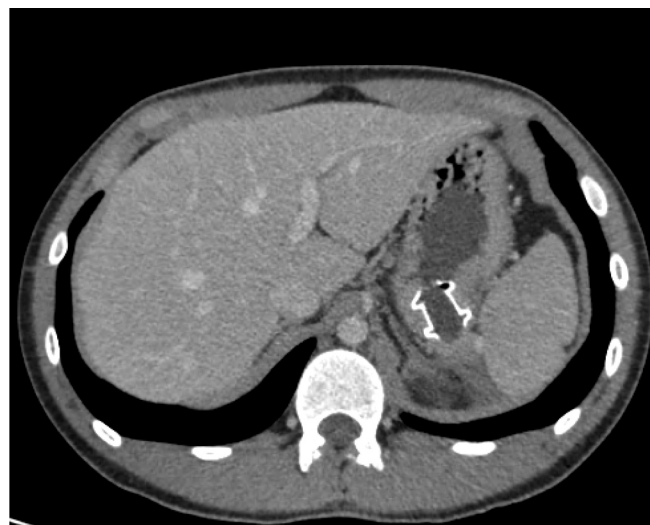**Figure 2.** EUS-guided cystogastrostomy with LASEMS.

within abdominal or pelvic cavities as well as in-between bowel loops. Collections within the space between the peritoneum and transversalis fascia are considered to be retroperitoneal.<sup>2</sup> Etiologies of either type of collection can be malignant, traumatic (blunt, perforation), or infectious (primary versus secondary). The most common retroperitoneal collection is pancreatic pseudocyst as a complication of acute pancreatitis.<sup>3,4</sup> Our case was an intraperitoneal hematoma with secondary bacterial and fungal infections. Retroperitoneal hematoma may be associated with trauma, ruptured abdominal aortic aneurysm, anticoagulation therapy, or blood dyscrasia. The CT appearance of an intraperitoneal hematoma depends on the time-elapsed between the traumatic event and imaging (in magnetic resonance imaging, subacute hematomas T1/T2 signals are bright).<sup>2</sup>

Infectious collections have been traditionally managed with antibiotics and surgical or percutaneous drainage, the latter performed by an interventional radiologist in order to avoid surgery. With the advent of endoscopic sonogram, another option has been added to the therapeutic armamentarium. Further, with the availability of LASEMS, EUS-guided drainage is becoming the procedure of choice for any collections which can be easily accessed through the gastrointestinal tract. EUS provides greater spatial resolution than the other imaging modalities used by interventional radiology. This allows clearer visualization of the needle and evaluation of blood flow along the path of the needle, avoiding intervening vasculature.<sup>3</sup> However, drainage alone may be insufficient when the collections are septated, thick, or embedded in between organs. In the presence of thick adherent debris,



**Figure 3.** Intracavitary thrombolytic instillation.



**Figure 4.** Contrast CT abdomen pelvis, 8week post initial procedure.



surgeons and interventional radiologist have employed thrombolytics to facilitate complete drainage.

The use of urokinase has been reported to dissolve blood clots obstructing a palliative biliary stent<sup>7</sup> and in the management of loculated para-pneumonic effusions in children.<sup>8</sup> This was before its removal from the US market due to non-selective nature and significant risk of bleeding. It has been replaced by tPA, which is a safer alternative because of more selective targeting.<sup>5-8</sup> A single chain form of endogenous enzyme, tPA converts fibrin bound plasminogen to its active form plasmin, resulting in fibrinolysis and dissolution of clots. It acts specifically on the plasminogen bound to the clots. It has been used widely by interventional radiologists and surgeons as an adjunctive fibrinolytic agent in both pediatric and adult populations for intrapleural collections.<sup>6</sup> Moparty et al. successfully used tPA in dissolving an intrabiliary clot, caused by hemobilia, through a nasogastric catheter.<sup>9</sup> One retrospective study<sup>10</sup> evaluated all patients over a 10 year period who had intraperitoneal collections treated with tPA for drainage, in which 64 children had 66 drains placed with 92 doses of tPA. Most of these collections were caused by appendicitis. None of the patients experienced bleeding complications or coagulopathy post administration.

In 2011, the second Multicenter Intrapleural Sepsis Trial concluded that tPA in combination with DNase improves fluid drainage in patients with pleural infection compared to treatment with tPA alone.<sup>5</sup> Rahman et al.<sup>6</sup> in their double-blind, randomized trial found that, compared to placebo, the combination of tPA and DNase improved drainage of empyemas, reducing length of hospital stay with improvement of natural history of pleural infection. This combination has been successfully employed in the management of peritonitis in patients on peritoneal dialysis.

Our patient's case was different from common EUS-guided drained collections. It was an organized infected hematoma, as opposed to collections formed in context of an episode of pancreatitis. There were concerns that forceful removal of the solid debris might rupture the capsule of the collection, leading to extravasation and septic peritonitis. In the literature, we noted positive outcomes with use of thrombolytics in pleural loculated effusions, empyemas, and intra-abdominal abscesses. The criteria to use tPA included extremely viscous contents with limited to no drainage in the post-procedure imaging. The use of thrombolytics is based on the fibrinolysis mechanisms that promotes breakdown of septations and thick debris, facilitating drainage.<sup>4</sup>

We undertook two attempts at debris dissolution, first with tPA and second with combination of tPA and DNase. These

were instilled through the scope into cystogastrostomy created with LASEMS. At present, there is no optimal standardized treatment protocol for these procedures.<sup>5</sup> By applying this technique, we minimized recurrent interventions, decreasing risk of complications as well as duration of hospital stay.

In conclusion, the present case demonstrates the successful and safe use of EUS-guided transgastric drainage in conjunction with the employment of fibrinolytics/thrombolytics for the dissolution of thickened internal debris instead of mechanical debridement, which could have compromised the capsule leading to generalized peritonitis. To the best of our knowledge, this report is the first to describe endoscopic drainage utilizing thrombolytics. In the future a case series will help evaluate long term results.

## References:

1. Yang DM, Jung DH, Kim H, et al. Retroperitoneal cystic masses: CT, clinical pathologic findings and literature review. *RadioGraphics*. 2004;24:1353–1365.
2. Mallia AJ, Ashwood N, Arealis G, Galanopoulos I. Retroperitoneal abscess: an extra-abdominal manifestation. *BMJ Case Rep*. 2015;2015(jan09 1):bcr2014207437–bcr2014207437.
3. Sagami R, Tsuji H, Nishikiori H, Murakami K. Endoscopic ultrasound-guided transduodenal drainage of idiopathic retroperitoneal abscess in an immunocompromised patient: a case report. *Medicine (Baltimore)*. 2017;96:e9132.
4. Kakar S, Manzo CE, Hashash JG. An unusual cause of a retroperitoneal fluid collection. *Gastroenter*. 2018;154:33–34.
5. Shenoy-Bhangle S, Gervais D. Use of fibrinolytics in abdominal and pleural collections. *Semin Intervent Radiol*. 2012;29:264–269.
6. Rahman NM, Maskell NA, West A, et al. Intrapleural use of tissue plasminogen activator and DNase in pleural infection. *N Engl J Med*. 2011;365:518–526.
7. Hsu RK, Lo KK, Lai CW, Leung JW. Late stent blockage by blood clot successfully treated by urokinase. *Gastrointest Endosc*. 1992;38:604–605.
8. Krishnan S, Amin N, Dozor A, Stringel G. Urokinase in the management of complicated parapneumonic effusions in children. *Chest*. 1997;112:1579–1583.
9. Moparty RK, Brown RD, Layden TJ, Chirravuri V, Wiley T, Venu RP. Dissolution of blood clots in the biliary ducts with a thrombolytic agent infused through nasobiliary catheter. *Gastrointest Endosc*. 2002;56:436–438.
10. Shawyer AC, Amaral JG, Langer JC. The role of tissue plasminogen activator in the management of complex intra-abdominal abscesses in children. *J Pediatr Surg*. 2012;47:1380–1384.