

# Robotic Extended-View Totally Extraperitoneal Transversus Abdominis Release (eTEP/TAR) Without Crossover for a Large Right Boundary Incisional Hernia

Vivek Bindal, FNB, Daksh Sethi, MS, Mukund Khetan, MS, Sudhir Kalhan, MS, Suviraj John, FNB, Rohit Dadhich, MS, B. Ramana, MS

Institute of Minimal Access, Metabolic and Bariatric Surgery, Sir Gangaram Hospital, New Delhi, India (Drs. Bindal, Sethi, Khetan, Kalhan, John, Dadhich).

Department of Minimally Invasive and Gastrosurgery, Apollo Gleneagles Hospital, Kolkata, India (Dr. Ramana).

## ABSTRACT

**Introduction:** The enhanced-view totally extraperitoneal (eTEP) approach is increasingly being used to tackle large ventral and incisional hernias. We are presenting a case of robot-assisted eTEP with unilateral transversus abdominis release (TAR) without crossover through all midline ports for an open appendectomy site boundary hernia.

**Materials and Methods:** Patient presented with a large incisional hernia at the open appendectomy site. Contrast-enhanced computed tomography revealed disruption of linea semilunaris on right side, with a 12-cm defect having large bowel and omentum as content of hernia sac. We planned a unilateral eTEP approach without crossover. We performed a diagnostic laparoscopy to inspect the contents of the hernia sac by inserting a 5-mm port in the left subcostal region. The peritoneal cavity was deflated, and access was made in the retro-rectus space via right subcostal region using optical entry. Three ports were inserted on the right side on linea alba, in the retro-rectus space. Robotic system was docked, eTEP space developed, and right-sided TAR was done saving the neurovascular bundles. The posterior rectus sheath complex and anterior defect was closed using barbed sutures. A 20 × 25-cm medium weight polypropylene mesh was placed.

**Result:** The operative time was 160 min and estimated blood loss was 50 mL. Postoperative stay in the hospital was uneventful and the patient was discharged on postoperative day 2. She is doing well at 9 mo followup. This case was unique as it was a unilateral eTEP/TAR without crossover, using robotic approach. We could not find any published report of similar approach of posterior component separation using robot.

**Conclusion:** Robotic eTEP/TAR is a safe and feasible approach to tackle large incisional hernias. Robotic system provides distinct advantages in dissection, identifying the planes and suturing in eTEP space.

**Key Words:** hernia, ventral hernia, incisional hernia, robotic hernia surgery, extended-view totally extraperitoneal, eTEP, eRS, eTAR, AWR, abdominal wall reconstruction.

**Citation** Bindal V, Sethi D, Khetan M, Kalhan S, John S, Dadhich R, Ramana B. Robotic extended-view totally extraperitoneal transversus abdominis release (eTEP/TAR) without crossover for a large right boundary incisional hernia. CRSLS e2020.00025. DOI: 10.4293/CRSLS.2020.00025.

**Copyright** © 2020 by SLS, Society of Laparoendoscopic Surgeons. This is an open-access article distributed under the terms of the Creative Commons Attribution-Noncommercial-ShareAlike 3.0 Unported license, which permits unrestricted noncommercial use, distribution, and reproduction in any medium, provided the original author and source are credited.

Disclosure: none.

Funding/Financial Support: none.

Conflicts of Interest: The authors declare no conflict of interest.

Informed consent: Dr. Sethi declares that written informed consent was obtained from the patient/s for publication of this study/report and any accompanying images.

Address correspondence to: Daksh Sethi, MS, Institute of Minimal Access, Metabolic & Bariatric Surgery (iMAS) Room No. 400 (IV Floor), SW Block Sir Ganga Ram Hospital, Rajinder Nagar, New Delhi -110060. India. E-mail: dakshsethi279@gmail.com, Fax: 91-11-2586 8768, Phone: +919873144244.

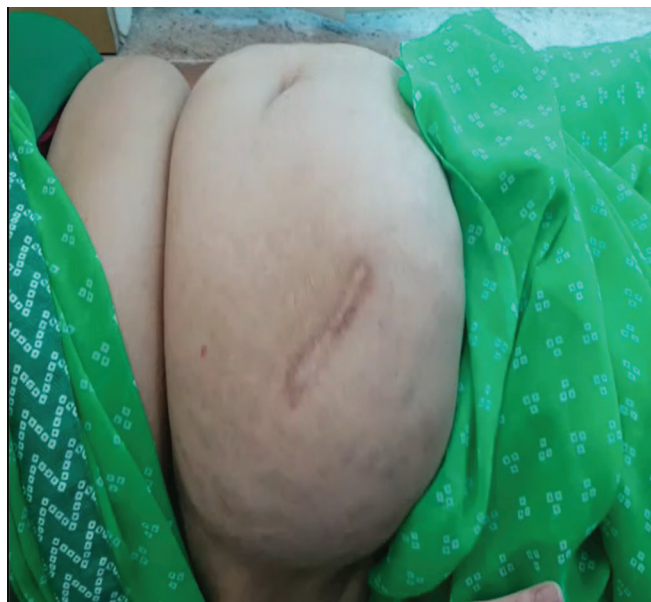## INTRODUCTION

Hernia and its treatment as a concept have been present since the beginning of our time.<sup>1</sup> Minimal-access hernia surgery has a goal of a robust repair with minimal complications. The extended-view totally extraperitoneal (eTEP) technique allows entry into the preperitoneal or retro-rectus space from any portion of the anterior abdominal wall, while permitting additional room for dissection of more complex hernias. The eTEP approach is increasingly being used to tackle large ventral and incisional hernias.<sup>2</sup> A challenging situation encountered by abdominal wall reconstruction surgeons is the boundary hernia that occurs following subcostal or lumbar trans- and extraperitoneal approaches during elective surgery, or as an outcome of emergency surgical reconstruction of traumatic lesions in an area extending from the intercostal region to the iliac crest, i.e., the lateral abdominal wall.<sup>3</sup> The laparoscopic eTEP access approach to ventral hernias is a versatile method to address a wide variety of abdominal wall defects, but retains its limitations because of straight instruments with limited degrees of freedom and difficult suturing in small spaces.

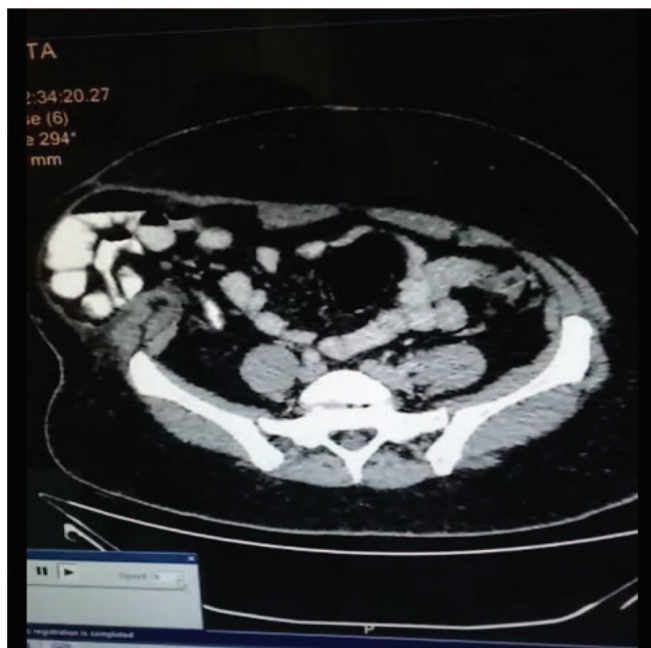New robotic techniques are being developed in complex abdominal wall hernias with promising results. Endo-wristed movements, three-dimensional visualization, and excellent ergonomics for the surgeon have contributed to this technique becoming a more adoptable technique than its laparoscopic counterpart.<sup>4</sup> The robotic platform potentially offers some advantage over laparoscopy, with the ability to perform intracorporeal suturing quickly and effectively.<sup>5</sup>

## CASE REPORT

The patient was a 43-year-old female (height, 155 cm; weight, 70 kg; BMI (Body Mass Index), 29.1 kg/m<sup>2</sup>) who presented with an incisional hernia, M4, L2,3,4 (EHS (European Hernia Society) Classification)<sup>6</sup> at the open appendectomy site. The patient underwent open appendectomy in 2018 and developed surgical-site infection in the postoperative phase, which was managed conservatively. On examination, a large defect was palpable at the previous incision site with cough impulse (**Figure 1**). Contrast-enhanced computed tomography of the abdomen was done, which revealed disruption of linea semilunaris on the right side, with a 12-cm defect in the right lateral abdominal wall having small bowel, large bowel, cecum, and omentum as contents of hernia sac (**Figure 2**). The defect margin inferiorly was the iliac crest, lateral abdominal wall muscles were thinned out and retracted while the rectus muscle and sheath on the



**Figure 1.** Preoperative picture of the patient.

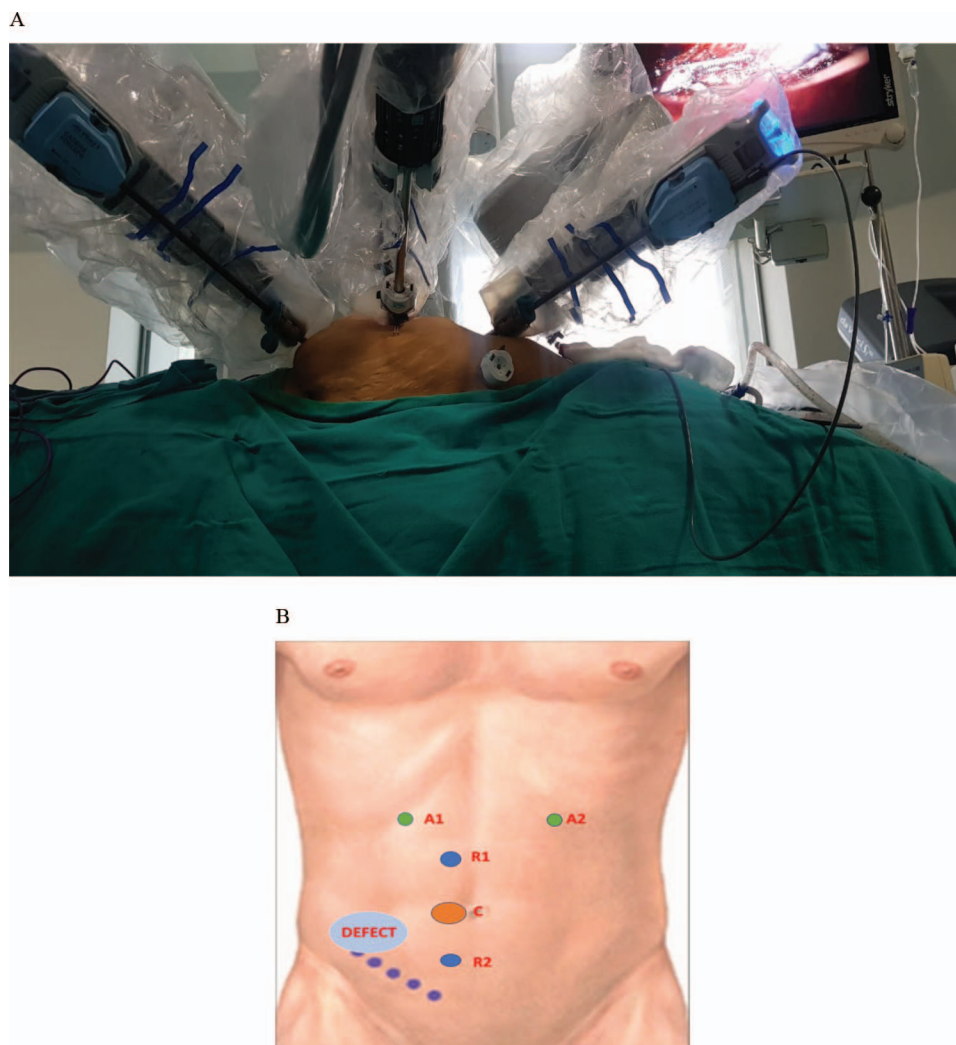


**Figure 2.** Preoperative CT scan showing large right-sided incisional hernia (M2 L2,3,4).

right side were well preserved. We planned a robotic unilateral eTEP approach without crossover.

## SURGICAL TECHNIQUE

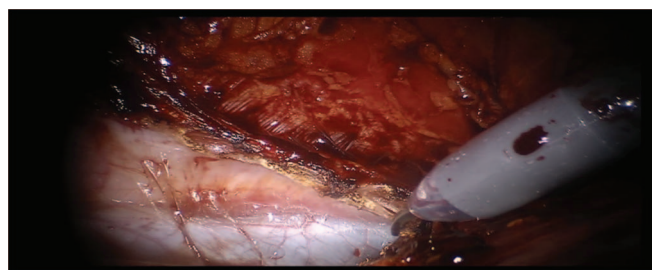
The patient is positioned semilateral position with 45° left tilt and arms tucked to the sides. Urinary catheter was



**Figure 3.** A, Port position and docked robotic system; B, diagrammatic representation of port position.

placed and the table was flexed in a manner so as to open the space between the subcostal margin and iliac crest. Relevant anatomy was marked, including the xiphoid process, bilateral subcostal margins, symphysis pubis, iliac crests, linea alba, and semilunar lines. Pneumoperitoneum was created from the left subcostal region using a Veress needle, and a diagnostic laparoscopy was done to inspect the contents of the hernia sac after inserting a 5-mm port. The peritoneal cavity was then deflated, and access was made in the retro-rectus space via the right subcostal region using optical entry. Three 8-mm ports (supra-umbilical, umbilical, and suprapubic) were inserted on the right side of the linea alba, in the retro-rectus space. The Da Vinci Si Robotic system was docked (**Figure 3, A and B**), and extended-view totally extraperitoneal (eTEP) space was developed using monopolar scissors and Cadie

grasper. The hernia sac was dissected down, and the contents were reduced after adhesiolysis. Right-sided transversus abdominis release (TAR) was done, saving the neurovascular bundles along the way to prevent the denervation of the rectus abdominis muscle (**Figure 4**). The entire right



**Figure 4.** Robotic transversus abdominis muscle release.



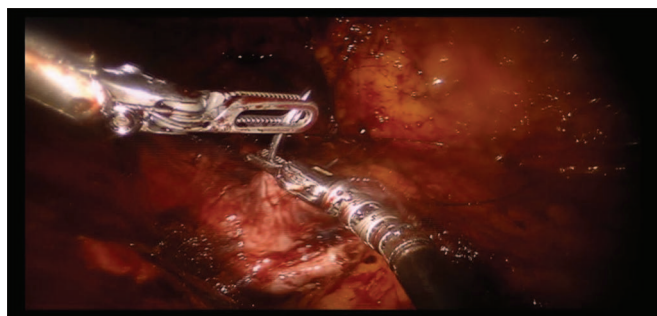
extraperitoneal space was developed till the lateral border of the psoas muscle was reached, the pelvic spaces of Retzius and Bogros were laid open, and the subcostal, subdiaphragmatic spaces were dissected out. The posterior rectus sheath-peritoneum complex and anterior hernia defect were closed using barbed sutures (**Figure 5** and **Figure 6**). A 20 × 25-cm medium-weight macroporous polypropylene mesh was placed without fixation in the retro-muscular space created (**Figure 7**). No drains were placed.

## RESULTS

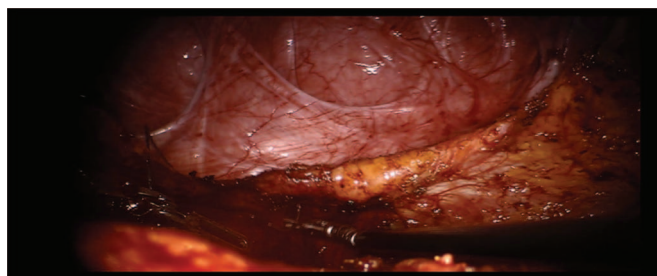
The operative time was 160 min and estimated blood loss was 50 mL. The patient was ambulated the same day in the evening. She had limited pain and did not receive any analgesics beyond the second postoperative day. Postoperative stay in the hospital was uneventful and the patient was discharged on postoperative day 2. She is doing well at 9 mo followup (**Figure 8**). There was no bulge present at the previous hernia site even on coughing or standing up.

## DISCUSSION


This defect of the linea semilunaris was challenging to deal with because of damage to the lateral abdominal muscles and proximity to the iliac crest. Various approaches have been tried for these boundary hernias in-



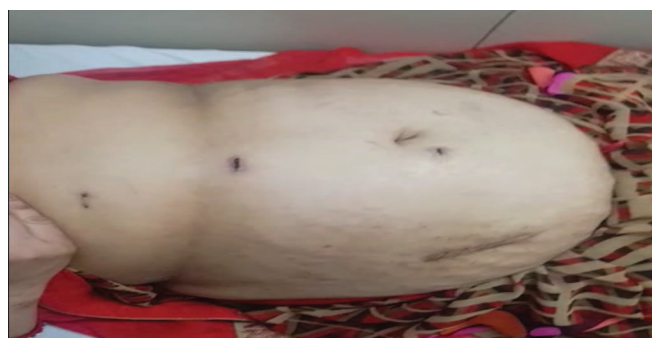**Figure 5.** Closure of the peritoneal defect.



**Figure 6.** Closure of the anterior abdominal wall defect.



**Figure 7.** Placement of mesh in the retro muscular space.



**Figure 8.** Postoperative picture of the patient.

cluding bridging repairs (intraperitoneal onlay mesh repair) with or without defect closure. The problem faced is that of pseudorecurrence and functionally poor result as the patient continues to feel a bulge in the postoperative period. Lateral hernias are very difficult to close, and adequate and stable mesh overlap is a limitation, leading to high recurrence rates.

Therefore, we have now moved to the eTEP approach where it is possible to provide adequate muscle and mesh cover after posterior component separation. Most of the time, eTEP approach involves crossover by cutting the posterior rectus sheath in the midline and connecting the retro-rectus space on both sides of the linea alba (the “crossover”). In this case, we decided to do a unilateral approach as the defect was in the region of the linea semilunaris and the entire width of the right posterior rectus sheath (which was approximately 8 cm in this case) was available as a margin to be covered with the mesh (as seen on preoperative CT (Computed Tomography) scan). We also added a diagnostic laparoscopy using a 5-mm port in the left subcostal region to be sure about the contents, which were small bowel, large bowel, cecum, and omentum in this case.

In our approach to eTEP, we do not fix the mesh and release the pneumoperitoneum under direct vision as-

sure the flat placement of the mesh between the anterior and posterior layers. A review of literature showed that Novitsky et al<sup>7</sup> fixed the mesh in open TAR using full-thickness, transabdominal fixation using slowly absorbing monofilament sutures. Belyansky et al<sup>2</sup> in their description of the eTEP approach described various methods of mesh fixation like transfascial sutures, tacks, or fibrin sealant glue but in recent experience, have migrated to no fixation. Our technique of no mesh fixation has provided good results and corroborated by other studies.<sup>8</sup>

Usually, the DaVinci Si robotic system requires triangulation of ports to avoid external arm clashing, while in this case, the ports were in a straight line. This challenge was overcome by adequate spacing of the ports and using only 2 instrument arms with the camera. The flex in the table also helped in providing space for the docked robotic arms. This technique provides good cosmesis and satisfactory result to the patient by providing adequate muscle and mesh coverage to the defect.

The robot offers advantages including a three-dimensional view, accurate and precise dissection, stable platform, and seven degrees of freedom of motion within reduced space.<sup>9–11</sup> Visualization is steady and allows depth perception that is lacking in traditional laparoscopy. Additionally, this technology provides adaptive downscaling of the surgeon's movement, eliminating tremor. The degrees of freedom of each instrument permit virtually every angle desired for retraction, dissection, and suturing in difficult areas. We could not find any published report of a similar approach of eTEP/TAR without crossover using robot.

## CONCLUSION

Robotic eTEP/TAR is a safe, feasible, and effective technique to deal with lateral/boundary ventral hernias.

## References:

1. Lichtenstein IL, Shulman AG. Ambulatory outpatient hernia surgery. Including a new concept, introducing tension-free repair. *Int Surg*. 1986;71:1–4.
2. Belyansky I, Daes J, Radu VG, et al. A novel approach using the enhanced-view totally extraperitoneal (eTEP) technique for laparoscopic retro muscular hernia repair. *Surg Endosc*. 2018;32:1525–1532.
3. Ferulano GP, Dilillo S, Lionetti R, Ambra M, Fico D, Pelaggi D. Boundary incisional hernias. Diagnosis and therapy of a rare pathology. In: *Incisional hernia. Updates in surgery*. Milano, Italy: Springer; 2008.
4. Bindal V, Bhatia P, Kalhan S, et al. Robot-assisted excision of a large retroperitoneal schwannoma. *JSLS*. 2014;18:150–154.
5. Tayar C, Karoui M, Cherqui D, Fagniez PL. Robot-assisted laparoscopic mesh repair of incisional hernias with exclusive intracorporeal suturing: A pilot study. *Surg Endosc*. 2007;21:1786–1789.
6. Muysoms FE, Miserez M, Berrevoet F, et al. Classification of primary and incisional abdominal wall hernias. *Hernia*. 2009;13:407–414.
7. Novitsky YW, Fayeziadeh M, Majumder A, Neupane R, Elliott HL, Orenstein SB. Outcomes of posterior component separation with transversus abdominis muscle release and synthetic mesh sublay reinforcement. *Ann Surg*. 2016;264:226–232.
8. Penchev D, Kotashev G, Mutafchiyski V. Endoscopic enhanced-view totally extraperitoneal retromuscular approach for ventral hernia repair. *Surg Endosc*. 2019 Jan 24. Published online 2019;33:3749–3756.
9. Bhatia P, Bindal V, Singh R, et al. Robot-assisted sleeve gastrectomy in morbidly obese versus super obese patients. *JSLS*. 2014;18:e2014.00099.
10. Bindal V, Bhatia P, Dudeja U, Kalhan S, et al. Review of contemporary role of robotics in bariatric surgery. *J Min Access Surg*. 2015;11:16–21.
11. Lanfranco AR, Castellanos AE, Desai JP, Meyers WC. Robotic surgery: A current perspective. *Ann Surg*. 2004;239:14–21.