

AirSeal was Useful in Laparoscopic Surgery for Perforated Appendicitis During Pregnancy

Kengo Kai, MD, Takuto Ikeda, MD, Akiko Ichihara, MD, Roko Hamada, MD,
Kenzo Nagatomo, MD, Satoshi Matsuzawa, MD, Junko Ushijima, MD, Seishi Furukawa, MD,
Hiroshi Sameshima, MD, Atsushi Nanashima, MD

Department of Surgery, University of Miyazaki Faculty of Medicine, Kiyotake, Miyazaki City, Miyazaki, Japan (Drs Kai, Ikeda, Ichihara, Hamada, Nagatomo, and Nanashima).

Department of Obstetrics and Gynecology, University of Miyazaki Faculty of Medicine, Kiyotake, Miyazaki City, Miyazaki, Japan (Drs Matsuzawa, Ushijima, Furukawa, and Sameshima).

ABSTRACT

Introduction: Acute appendicitis is the most common general surgical problem during pregnancy. Laparoscopic appendectomy has been gaining widespread popularity and has been accepted as a minimally invasive surgery based on evidence for its use in appendicitis in pregnant patients. However, the gravid uterus in the third trimester and the frequent suction required for abscess drainage make the working space intractable.

Case Description: We report a case in which an AirSeal intelligent flow system (ASIFS) (CONMED Corporation, Utica, NY, USA) was useful for laparoscopic appendectomy and abscess drainage for perforated appendicitis in a 31-wk pregnant patient. ASIFS allowed successful maintenance of a working space, thus making it possible to excise the appendix at its base with double ligation and effectively drain the abscess with no maternal and fetal complications. To our knowledge, there have been no reports of the use of ASIFS in a pregnant patient. A past study reported that ASIFS could induce hypothermia compared with a conventional CO₂ supply tube in patients. Although intraoperative hypothermia did not occur in our patient, it would be prudent to carefully avoid frequent suctioning in the short term and to warm the patient intraoperatively because maternal and fetal bodies are susceptible to change in hemodynamics.

Conclusion: Surgeons should consider the use of ASIFS before deciding to convert from laparoscopic appendectomy to an open procedure in pregnant patients.

Key Words: laparoscopic appendectomy, perforated appendectomy, third trimester, AirSeal intelligent flow system.

Citation Kai K, Ikeda T, Ichihara A, Hamada R, Nagatomo K, Matsuzawa S, Ushijima J, Furukawa S, Sameshima H, Nanashima A. AirSeal was useful in laparoscopic surgery for perforated appendicitis during pregnancy CRSLS e2020.00008. DOI: 10.4293/CRSLS.2020.00008.

Copyright © 2020 by SLS, Society of Laparoendoscopic Surgeons. This is an open-access article distributed under the terms of the Creative Commons Attribution-Noncommercial-ShareAlike 3.0 Unported license, which permits unrestricted noncommercial use, distribution, and reproduction in any medium, provided the original author and source are credited.

Disclosure: none.

Funding/Financial Support: none.

Conflicts of Interest: The authors declare no conflict of interest.

Informed consent: Dr. Kai declares that written informed consent was obtained from the patient/s for publication of this study/report and any accompanying images.

Address correspondence to: Kengo Kai, MD, Department of Surgery, University of Miyazaki Faculty of Medicine, 5200 Kihara, Kiyotake, Miyazaki City, Miyazaki 889-1692, Japan. Fax: +81-985-85-9186, E-mail: kengo_kai@med.miyazaki-u.ac.jp.

INTRODUCTION

Acute appendicitis is the most common general surgical problem during pregnancy, occurring in one of 1000 to 2000 pregnancies.¹ Appendicitis in a pregnant woman

demands careful diagnosis and treatment for the safety of the maternal and fetal lives. Laparoscopic appendectomy (LA) has been gaining widespread popularity and has been accepted as a minimally invasive surgery based on evidence for its use in appendicitis in pregnant patients.

We report a case of perforated appendicitis treated with LA and abscess drainage in a 31-wk pregnant patient. The gravid uterus in the third trimester and frequent suction for abscess drainage make the working space intractable. The AirSeal intelligent flow system (ASIFS) (CONMED Corporation, Utica, NY, USA) (**Figure 1**) is a novel laparoscopic CO₂ insufflation system that offers the advantage in maintaining a stable pneumoperitoneum, even under continuous suction.² In this case, ASIFS was very useful in maintaining a working space to allow successful completion of the operation with no maternal or fetal complications.

To our knowledge, there have been no reports of the use of ASIFS in a pregnant patient. We reviewed the course of treatment and the literature on the third trimester and perforated appendicitis during pregnancy.

CASE PRESENTATION

A 32-y-old Japanese woman at 31 wk of gestation was referred to her practitioner for complaints of abdominal pain and vomiting. Although she was initially diagnosed as having enteritis, the abdominal pain, especially that in the right lower quadrant, increased over 2 d. Computed tomography revealed a swollen appendix with many fecal calculi, lying dorsal to the ileocecal region but with no evidence of perforation or abscess formation (**Figure 2**). The patient was diagnosed as having acute appendicitis and transferred to our hospital for surgical treatment under obstetric management.

She had no relevant past medical history including gestational diabetes. Blood tests and chemistry on admission showed a white blood cell count of 19,600/ μ L and a serum C-reactive protein of 10.69 mg/dL, indicating high levels of inflammatory factors. Because of frequent uter-

ine contractions on admission, she was administered magnesium sulfate as tocolysis. We decided to perform emergency surgery for the diagnosis of acute appendicitis resistant to conservative treatment. Preoperatively, abdominal ultrasonography was performed to evaluate fundal height to enable insertion of the first trocar. Fetal heart Doppler ultrasound monitoring was also conducted perioperatively.

Following induction with general anesthesia, the patient was positioned in the supine position. The procedure was performed using three ports (**Figure 3**). With an open-entry technique, the first trocar was inserted cephalad to the umbilicus in the upper midline between the umbilicus and xiphoid process. Initially, the pneumoperitoneum was performed at 8 mm Hg with a conventional CO₂ supply tube. A laparoscope was inserted through the middle trocar, and then the second and third trocars were inserted under direct visualization. The patient was inclined toward the left to avoid compression of the inferior vena cava by the gravid uterus. The appendix was strongly adhered to the retroperitoneum and was lying dorsal to the terminal ileum. With blunt dissection, the abscess was discharged from localized space (**Figure 4A**). Although frequent suction need to be performed for drainage, the gravid uterus, cecum, and ileum narrowed the working space around the appendix and abscess with even the slightest loss of CO₂ gas (**Figure 4B**). To ensure a safe laparoscopic procedure, we replaced the trocar in right upper abdomen with a 15-mm AirSeal trocar at 10 min after the start of insufflation, and ASIFS helped to establish a more stable pneumoperitoneum at 8 mm Hg. Successful maintenance of the working space allowed us to excise the appendix at its base with double ligation and to drain abscess effectively (**Figure 4, C and D**). The operation was completed after a drainage tube was inserted in the abscess cavity. Total operative time was 63 min, and estimated blood loss was 0 mL. The patient's average body temperature was 37.0 \pm 0°C with the conventional CO₂ supply system and 37.0 \pm 0.04°C with the ASIFS. Pathological findings revealed gangrenous appendicitis with perforation.

Postoperatively, the obstetricians added ritodrine hydrochloride to further decrease uterine contractions, but all tocolysis could be stopped by postoperative day 2. Although she temporarily suffered paralytic ileus, flatus and first bowel movement returned on each 3 and 5 d after surgery. She was discharged to home on postoperative day 10. Under obstetrical management, she delivered a healthy baby in her 39th week by caesarean section because of breech presentation without complications.

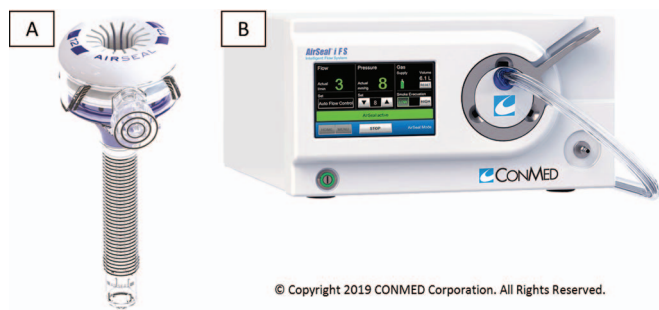


Figure 1. AirSeal intelligent flow system. AirSeal intelligent flow system (ASIFS) is a laparoscopic CO₂ insufflation system composed of the AirSeal valveless Trocar (**A**) and the ASIFS control module and the AirSeal mode evacuation trilumen filter tube set (**B**).

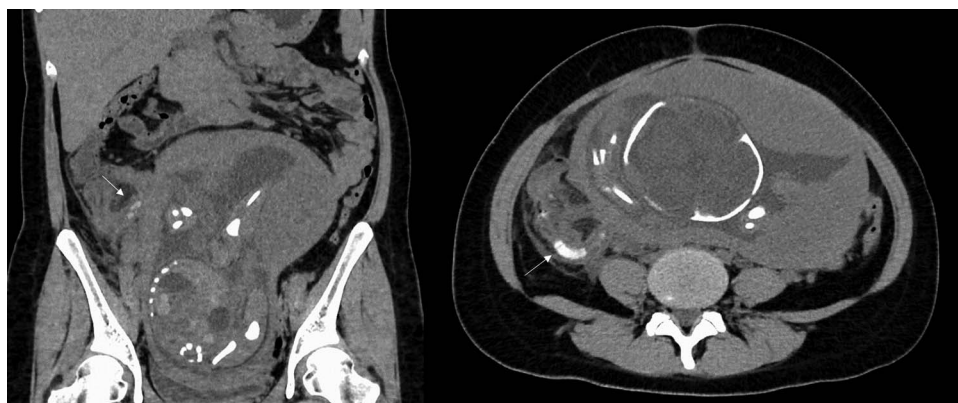

Figure 2. Computed tomography findings. Computed tomography revealed the gravid uterus occupying the pelvis and the swollen appendix with many fecal calculi (arrow), lying dorsal to the ileocecal region. It showed no evidence of perforation or abscess formation.

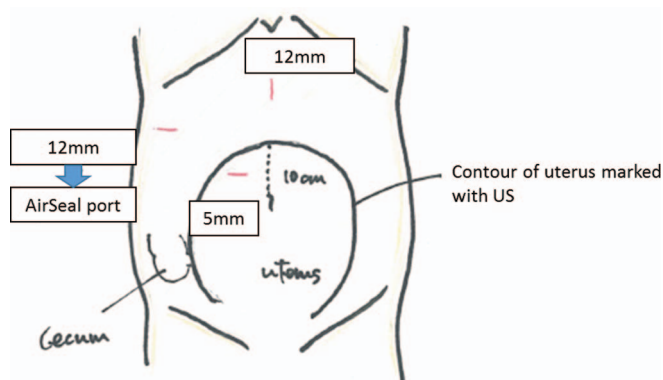


Figure 3. Trocar positions. Three trocars were placed after marking the contour of the uterus with ultrasonography. We reinserted a 15-mm AirSeal port at the right upper abdomen for use of the AirSeal intelligent flow system.

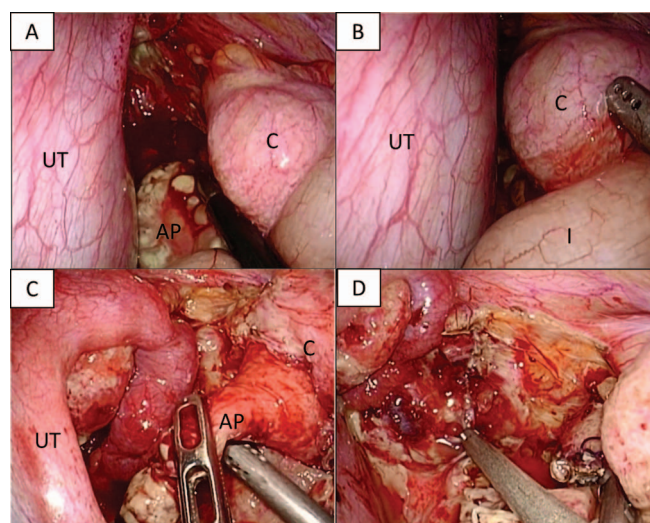


Figure 4. Intraoperative findings. Laparoscopic appendectomy was performed at 31 wk of gestation. (A) The appendix was adhered strongly to the retroperitoneum, and blunt dissection made localized abscess discharged. (B) With even slight suction, the uterus, cecum, and ileum narrowed the working space. (C and D) The AirSeal intelligent flow system established a more stable pneumoperitoneum, allowing the use of continuous suction. AP, appendix; UT, uterus; C, cecum; I, ileum.

DISCUSSION

Acute appendicitis is a common nonobstetric indication for surgical intervention during pregnancy that can cause serious potential complications such as maternal and fetal morbidity and even fetal loss. Therefore, a prompt and adequate treatment policy must be determined through close cooperation between the surgeon, obstetrician, and anesthesiologist. There are important concerns related to the surgical procedure such as visualization of the abdomen, diagnostic accuracy, surgical trauma, postoperative pain, and recovery from surgical stress. Compared with open appendectomy (OA), LA is superior in many ways because it reduces the incidence of postoperative wound infection and wound pain, shortens the length of hospital stay, and enables quicker social rehabilitation. Corneille et al.³ reported that the perinatal complication rate, includ-

ing premature birth, fetal loss, and eclampsia, was 22.2% (two of nine) for LA and 27.5% (11 of 40) for OA. Additionally, Sadot et al.¹ and Kirshtein et al.⁴ concluded that LA appears to be a safe, feasible, and efficacious approach in large hospital-based series evaluating LA versus OA for pregnant patients with presumed acute appendicitis. In contrast, McGory et al.⁵ reported that the fetal loss rate in a single large study was substantially higher in patients undergoing LA (7%) than in patients undergoing OA (3%).

In a breakdown of the LA group in that study, fetal loss occurred in 13% of patients with complicated appendicitis, in 8% with a normal appendix, and in 4% with simple appendicitis. The data seem to imply that LA for simple appendicitis, at least, is equivalent to OA in terms of the safety of fetal life.

Acute appendicitis during pregnancy is thought to tend to progress to perforation or abscess formation because of the desire to avoid surgery during pregnancy owing to the risks of maternal and fetal complications. Silvestri et al.⁶ analyzed appendectomy data for pregnant and nonpregnant patients from the American College of Surgeons National Surgical Quality Improvement Program and reported that perforation of the appendix with abscess or generalized peritonitis occurred in 4.1% of pregnant patients versus in 2.7% of nonpregnant patients. According to a retrospective survey by Cox et al.,⁷ LA appears safe, even in cases of pregnant patients with perforation. That report showed that LA (n = 70) was superior to OA (n = 49) for patients with perforation in terms of length of stay and was equivalent in terms of overall complications, wound complications, and operative time.

In regard to the effect of LA on adequate gestation during pregnancy, the Society of American Gastrointestinal and Endoscopic Surgeons guideline⁸ stated that “laparoscopy can be safely performed during any trimester of pregnancy.” Similarly, the British Society for Gynaecological Endoscopy guideline⁹ indicated that “recent small series have shown good maternal and fetal outcomes for laparoscopic appendectomy up to 34 wk gestation.” However, some studies recommended that in the third trimester, LA should be converted to OA once the intraoperative diagnosis of appendicitis is made.¹⁰ However, we believe that the surgical procedure should be decided on the basis of individual case-by-case assessment of maternal and fetal condition, and the surgeon’s experience, the technique used, and the availability of devices that can provide adequate working space to complete the operation, regardless of the severity of the appendicitis and length of gestation.

ASIFS is a laparoscopic CO₂ insufflation system composed of the ASIFS control box, an AirSeal valveless Trocar, and the AirSeal mode evacuation trilumen filter tube set. This system presents some advantages in maintaining a stable pneumoperitoneum, even under continuous suction and continuous smoke evacuation throughout a surgical procedure. In our institution, ASIFS was introduced for laparoscopic surgery mainly for malignant disease from 2013, and we realized its usefulness in improving visibility of the

surgical field. In the present patient, ASIFS contributed to the successful completion of LA for a perforated appendicitis with abscess formation in the third trimester in which the gravid uterus and frequent use of suction made the working space intractable. Otsuka et al.¹¹ reported that ASIFS, by which continuous suction increased the CO₂ circulation, could cause hypothermia compared with a conventional CO₂ supply tube in patients who underwent thoracoscopic esophagectomy. Although intraoperative hyperthermia did not occur in this case, it would be important to take care to avoid frequent suctioning in the short term and to warm the patient intraoperatively because the maternal and fetal bodies are susceptible to changes in hemodynamics. Despite the successful outcome of our case, it is still only one case, and we should refrain from being overly enthusiastic, at least until we have a significant number of cases and a more complete picture regarding advantages and possible limitations.

CONCLUSION

We successfully treated a 31-wk pregnant patient with perforated appendicitis by LA and abscess drainage with the aid of ASIFS. Surgeons should consider the use of ASIFS before deciding to convert from LA to an open procedure in pregnant patients.

References:

1. Sadot E, Telem DA, Arora M, Butala P, Nguyen SQ, Divino CM. Laparoscopy: a safe approach to appendicitis during pregnancy. *Surg Endosc*. 2010;24:383–389.
2. Horstmann M, Horton K, Kurz M, Padevit C, John H. Prospective comparison between the AirSeal® System valve-less Trocar and a standard Versaport plus V2 Trocar in robotic-assisted radical prostatectomy. *J Endourol*. 2013;27:579–582.
3. Corneille MG, Gallup TM, Bening T, et al. The use of laparoscopic surgery in pregnancy; evaluation of safety and efficiency. *Am J Surg*. 2010;200:363–367.
4. Kirshstein B, Perry ZH, Avinoach E, Mizrahi S, Lantberg L. Safety of laparoscopic appendectomy during pregnancy. *World J Surg*. 2009;33:475–480.
5. McGory ML, Zingmond DS, Tillou A, Hiatt JR, Ko CY, Cryer HM. Negative appendectomy in pregnant women is associated with a substantial risk of fetal loss. *J Am Coll Surg*. 2007;205:534–540.
6. Silvestri MT, Pettker CM, Brousseau EC, Dick MA, Ciarleglio MM, Erekson EA. Morbidity of appendectomy and cholecystectomy in pregnant and nonpregnant women. *Obstet Gynecol*. 2011;118:1261–1270.

7. Cox TC, Huntington CR, Blair LJ, et al. Laparoscopic appendectomy and cholecystectomy versus open: a study in 1999 pregnant patients. *Surg Endosc.* 2016;30:593–602.
8. Guidelines Committee of the Society of American Gastrointestinal and Endoscopic Surgeons, Yumi H. Guidelines for diagnosis, treatment, and use of laparoscopy for surgical problems during pregnancy: this statement was reviewed and approved by the Board of Governors of the Society of American Gastrointestinal and Endoscopic Surgeons (SAGES), September 2007. It was prepared by the SAGES Guidelines Committee. *Surg Endosc.* 2008;22:849–861.
9. Ball E, Waters N, Cooper N, et al. Evidence-based guideline on laparoscopy in pregnancy: commissioned by the British Society for Gynaecological Endoscopy (BSGE) endorsed by the Royal College of Obstetricians and Gynaecologists (RCOG). *Facts Views Vis Obgyn.* 2019;11:5–25.
10. Holzer T, Pellegrinelli G, Morel P, Toso C. Appendectomy during the third trimester of pregnancy in a 27-year old patient: case report of a “near miss” complication. *Patient Safe Surg.* 2011;5:11.
11. Otsuka K, Murakami M, Ariyoshi T, Kohmoto M. The usefulness of AirSeal intelligent Flow System in video assisted thoracoscopic esophagectomy. *J Jpn Surg Assoc.* 2015;76:1266–1271.