

# Cervical Diverticulum Presenting as a Large Pelvic Mass

Anar Gojayev, MD, Steven R. Inglis, MD, Amirah Abdullah, MD,  
Benny Yuen, MD, Olga Rodas, MD, Khaled Zeitoun, MD

Department of Obstetrics and Gynecology, Jamaica Hospital Medical Center, Jamaica, New York, USA (All authors).

## ABSTRACT

**Introduction:** A 30-year-old gravida 2 para 1 woman was referred to us for further evaluation of pelvic mass from another center. She gave a history of cesarean delivery, multiple pelvic infections, and suspected pelvic mass. Patient was taken to the operating room after initial evaluation and imaging. Cervical diverticulum was identified and treatment carried out laparoscopically. The patient experienced an uneventful recovery and was completely free of the symptoms for 6 months.

**Conclusion:** Cervical diverticulum should be considered as a differential diagnosis and laparoscopic surgery should be considered as a treatment of choice for Müllerian anomalies.

**Key Words:** Cervical Diverticulum; Laparoscopy; Pelvic Mass; Pelvic Infection.

**Citation** Gojayev A, Inglis SR, Abdullah A, Yuen B, Rodas O, Zeitoun K. Cervical diverticulum presenting as a large pelvic mass. CRSLS e2019.00014. DOI: 10.4293/CRSLS.2019.00014.

**Copyright** © 2019 by SLS, Society of Laparoendoscopic Surgeons. This is an open-access article distributed under the terms of the Creative Commons Attribution-Noncommercial-ShareAlike 3.0 Unported license, which permits unrestricted noncommercial use, distribution, and reproduction in any medium, provided the original author and source are credited.

**Disclosures:** The authors have nothing to disclose.

**Conflicts of Interest:** All authors declare no conflict of interest regarding the publication of this article.

**Informed consent:** Dr. Gojayev declares that written informed consent was obtained from the patient for publication of this study/report and any accompanying images.

**Address correspondence to:** Anar Gojayev, MD, Department of Obstetrics and Gynecology, Jamaica Hospital Medical Center, 89-06 Van Wyck Expy, Jamaica, NY 11418. Telephone: 7182066808, Fax: 7182066829, E-mail: agojayev@jhmc.org

## BACKGROUND

True uterine diverticulum is a rarely seen anomaly. Exact prevalence is unknown but it is estimated to be around 0.1% to 3.0%.<sup>4</sup> In most the reported cases, diverticulum was found to be arising from the uterus alone or associated with cervical pathology.<sup>4</sup>

Most previously reported cases were called “pregnancy-associated sacculations,” and only few cases were considered true uterine diverticula.<sup>1</sup>

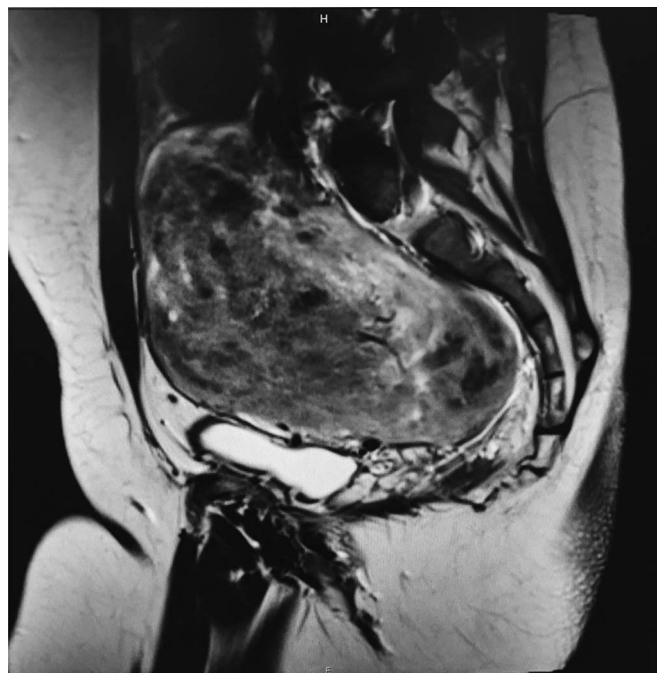
Uterine and cervical diverticula are usually small, asymptomatic, and are commonly observed in women who had previous surgical intervention, particularly caesarean section.<sup>1</sup> True uterine diverticula are very rare congenital Müllerian anomalies that require pathological confirmation. Diverticula may present as ectopic pregnancy, dysmenorrhea, abnormal uterine bleeding, and infertility.<sup>3</sup>

Congenital cervical abnormalities are even less common and are associated with coexisting uterine anomalies in 90% of the cases.

In this report we present a case of uterine cervical diverticulum presenting with acute abdominal emergency mimicking a huge cyst pelvic abscess. Such a huge diverticulum communicating with cervical canal at 2 different sites is a rare entity. Various clinical and diagnostic difficulties are also discussed.

## CASE

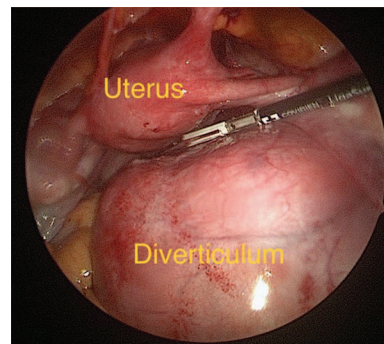
A 30-year-old south-Asian woman was referred to us for further evaluation of pelvic mass from another center. She was gravida 2 and para 1 with one previous full-term cesarean delivery and 1 dilatation and curettage for missed abortion in her home country. The patient complained of pelvic pain, which was acute at presentation.



**Figure 1.** Pelvic MRI, Sagittal view.

After her cesarean delivery the patient was told she had 2 uteruses and she was pregnant on the left side. Pregnancy records mentioned a duplication of uterus but not the cervix, pregnancy was in the left horn and cesarean section was performed. She had no other medical problems. Physical examination showed a large pelvic mass and one cervix. Office ultrasound showed possible uterine anomaly with left-sided hematometra and the right side appeared normal. Pelvic magnetic resonance imaging (MRI) with and without contrast obtained. The uterus was found to be 13 cm × 7 cm × 13 cm. MRI also showed an 11 cm × 7 cm × 14 cm thick walled mass at the right posterior lateral aspect of the uterus with hemorrhage within the central cavity which was communicating with the lower uterus at 2 sites (**Figure 1**). There was no evidence of uterine septum or bicornuate configuration. Ovaries appeared normal bilaterally. Differential diagnosis at that time included large pelvic communicating abscess, uterine degenerative fibroid versus other pelvic mass.

The patient underwent hysteroscopy and laparoscopy. On examination, uterine sound was easily inserted to the cavity. On hysteroscopy a large cavity with adhesions and no tubal openings seen. The main uterine cavity opening could not be found. On laparoscopy, the uterus was found to be normal with both fallopian tubes attached. A 15-cm mass was noted to be arising from the cervix at the level of uterosacral ligaments (**Figure 2**). Due to the



**Figure 2.** Intraoperative image.

history of multiple pelvic infections and sepsis the decision was made to remove this pelvic mass and it was sent for pathological examination.

## **PATHOLOGY REPORT**

Fragments of fibromuscular tissue with cystic cavities containing mucus and lined with a single layer of mucin-producing cells consistent with uterine-cervical diverticulum.

## **DISCUSSION**

In this report, we present an unusual case of a woman who presented with large isolated true cervical diverticulum. The clinical presentation consisted of long-standing history of recurrent pelvic abscesses and sepsis. The abscess was caused by infection the diverticular content.

In retrospect, we think that a careful examination of uterus, ovaries, and fallopian tubes at the time of cesarean section could have led to a proper diagnosis of this pelvic mass, considering that both fallopian tubes were connected to the uterus bilaterally and each fallopian tube was attached to the ovaries on each side. However, diverticulum was arising from the cervix and was not connected to the fallopian tubes.

Müllerian anomalies have been associated with various obstetrical and gynecological complications including recurrent pregnancy losses, infertility, ectopic pregnancies, premature rupture of membranes, and pelvic pain.<sup>5</sup>

Accurate diagnosis plays an important role for proper management of Müllerian anomalies. In our case, hysteroscopy and laparoscopy was crucial for final diagnosis; however, several different modalities of diagnostic methods can be utilized, including pelvic ultrasound and hysterosalpingography.

MRI technologies have been reported to be very successful in the diagnosing of Müllerian anomalies.<sup>8</sup> Currently, MRI is the preferred method of evaluation and is accepted as a gold standard. MRI was found to have a diagnostic accuracy of 96% to 100% in classifying and detailing of Müllerian duct anomalies including cervical agenesis.<sup>8</sup>

Embryologically, Müllerian canal development is passing through so-called three-stage process ductal development, ductal fusion, and septal reabsorption.

Müllerian duct growth is accompanied by midline migration and fusion of paired ducts to form the uterovaginal primordium. Interruption of the Müllerian duct fusion process gives rise to bicornuate uterus and didelphys Müllerian Duct Anomalies subtypes. Interruption of septal reabsorption could potentially cause diverticula.

Advancing technologies in minimally invasive gynecology and skills of the surgeons has allowed to perform many complex surgeries laparoscopically. Recovery time is much faster than traditional abdominal surgeries and potentially less adhesion formation can decrease future infertility.

Although Müllerian anomalies specially isolated cervical diverticula are very rare, we recommend ruling out the possibility of these anomalies when suspicion arises.

## References:

1. Umezaki I, Takagi K, Aiba M, et al. Uterine cervical diverticulum resembling a degenerated leiomyoma. *Obstet Gynecol.* 2004;103(5 Pt 2):1130–1133.
2. Suprapaneni K, Silberzweig JE. Cesarean section scar diverticulum: appearance on hysterosalpingography. *Am J Roentgenol.* 2008;190:870–874.
3. Engel G, Rushovich AM. True uterine diverticulum. A partial müllerian duct duplication? *Arch Pathol Lab Med.* 1984;108:734–736.
4. Seoud M, Awwad J, Adra A, et al. Primary infertility associated with isolated cervical collecting diverticulum. *Fertil Steril.* 2002;77:179–182.
5. The American Fertility Society classifications of adnexal adhesions, distal tubal occlusion, tubal occlusion secondary to tubal ligation, tubal pregnancies, müllerian anomalies and intra-uterine adhesions. *Fert Steril.* 1988;49:944–955.
6. Doyle MB. Magnetic resonance imaging in müllerian fusion defects. *J Reprod Med.* 1992;37:33–38.
7. Robbins JB, Parry JP, Guite KM, et al. MRI of pregnancy-related issues: müllerian duct anomalies. *Am J Roentgenol.* 2012;198:302–310.