

Delayed Perforation of Gastrocolocutaneous Fistula after Percutaneous Gastrostomy

Anthony M. Villano, MD, Ariana Metchik, MD, Ravinder Bamba, MD, Parag Bhanot, MD

Department of General Surgery, MedStar Georgetown University Hospital, Washington, DC, USA
(Drs Villano, Metchik, Bamba, and Bhanot)

ABSTRACT

Introduction: Percutaneous endoscopic gastrostomy (PEG) tube placement is generally a safe and effective method for establishing long-term enteral access in a minimally invasive fashion. Placement through an intervening loop of colon is a surgical pitfall that ultimately requires operative exploration to correct. Delayed perforation remote from the initial PEG placement is not yet described in the literature and represents an unusual but serious form of this complication.

Case Description: A 62-year-old male with history of Down syndrome and severe intellectual disability, chronic PEG, and tracheostomy developed free air during his admission. Subsequent exploratory laparotomy demonstrated that the PEG traversed the sigmoid colon and entered the gastric lumen, with a small perforation along the exit site of the sigmoid colon. Segmental colonic resection with end colostomy was performed without complication, and the gastrostomy was revised in a Stamm fashion. He was able to resume tube feeds prior to hospital discharge.

Conclusion: Intestinal perforation secondary to a misplaced PEG tube with gastrocolocutaneous fistula can occur in a delayed fashion, even long after the tube was placed and feeding was initiated. Utilization of the “safe tract” method must carefully be employed to minimize the risk of placement through an intervening hollow viscous such as colon or small bowel. Perforation or coloenteric fistulae require surgical intervention to correct.

Key Words: Gastrostomy, Cutaneous Fistula, Endoscopy.

Citation Villano AM, Metchik A, Bamba R, Bhanot P. Delayed perforation of gastrocolocutaneous fistula after percutaneous gastrostomy. CRSLS e2018.00091. DOI: 10.4293/CRSLS.2018.00091.

Copyright © 2019 by SLS, Society of Laparoendoscopic Surgeons. This is an open-access article distributed under the terms of the Creative Commons Attribution-Noncommercial-ShareAlike 3.0 Unported license, which permits unrestricted noncommercial use, distribution, and reproduction in any medium, provided the original author and source are credited.

Conflicts of Interest: The authors do not cite any conflicts of interest.

Financial Support: No financial support was utilized in the production of this manuscript.

Informed consent: Dr. Villano declares that written informed consent was obtained from the patient/s for publication of this study/report and any accompanying images.

Address correspondence to: Anthony M. Villano, MD, Department of General Surgery, MedStar Georgetown University Hospital, 3800 Reservoir Rd NW, PHC Building, Fourth Floor, Washington, DC 20007, USA. Telephone: 202-444-5045; Fax: 877-376-2421; E-mail: anthony.m.villano@gunet.georgetown.edu.

INTRODUCTION

Percutaneous endoscopic gastrostomy (PEG) has become the procedure of choice for establishing long-term enteral feeding access since it was first introduced in 1980 by Gauderer and others.¹ Largely, this is secondary to excellent efficacy (over 99% by meta-analysis)² in conjunction with technical simplicity, ease of tube management, and low cost.³ In comparison to other techniques for placement of gastrostomy tubes, PEG has garnered the most favorable risk profile with fewer tube dislodgements than radiographically guided tubes.⁴

Injury to the bowel with resultant peritonitis is the most dreaded complication of PEG placement, and fortunately is quite rare. Such an injury can occur if any loop of bowel traverses the peritoneal cavity anterior to the anticipated gastrostomy site on the stomach and is inadvertently entered when attempting to cannulate the gastric lumen. Generally, perforation of the bowel begets peritonitis in the perioperative period, requiring emergent surgery. A rarer variant of bowel injury is gastrocolocutaneous fistula (GCCF), whereby the PEG tube is placed into the stomach through the entire lumen of the colon, however peritonitis does not develop

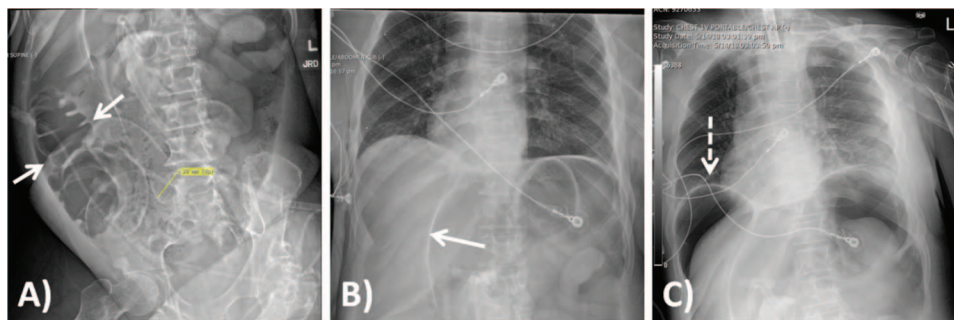


Figure 1. Preoperative plain films demonstrating free air. (A) Supine abdominal film demonstrating Rigler's sign (solid white arrows). (B) Falciform ligament sign (solid white arrow). (C) Upright chest x-ray reveals massive free air under the right hemidiaphragm (dotted white arrow).

and a subsequent colonic fistula forms. A handful of case reports exist describing this phenomenon.⁵⁻⁹ Often, this complication presents months after the initial PEG placement as recurrent emesis and frequent diarrhea, with potential for subacute febrile episodes.

Herein we present an as-of-yet undescribed case of delayed colonic perforation secondary to GCCF after PEG placement. We then review PEG tube complications and the literature surrounding presentation and management of GCCF.

CASE REPORT

The patient was a 62-year-old gentleman with history of developmental delay and prior PEG and tracheostomy placement who presented from a long-term care facility with tracheostomy complications. The patient had been tolerating tube feeds for several years via his PEG prior to presentation. On hospital day 2, the general surgery service was consulted for new-onset tachycardia. Abdominal plain films as well as an upright chest x-ray revealed a large volume of pneumoperitoneum (**Figure 1**). Given these findings, the patient was taken emergently to the operating room.

At exploratory laparotomy, a GCCF was noted almost immediately upon entering the abdomen. Examination of the fistula revealed a perforation of the sigmoid colon at the proximal aspect of the sigmoid colon as the PEG exited the anterior gastric wall and penetrated the colonic lumen (**Figure 2**). The fistula was completely taken down, a new gastrostomy tube was placed in a Stamm fashion, and a partial sigmoid colectomy with end colostomy was performed given his poor functional status/wound care needs. The patient tolerated this procedure well and was eventually discharged to his long-term care facility tolerating goal tube feeds.

DISCUSSION

With over 200,000 PEGs placed annually in the United States since the early 2000s,¹⁰ PEG tube placement has

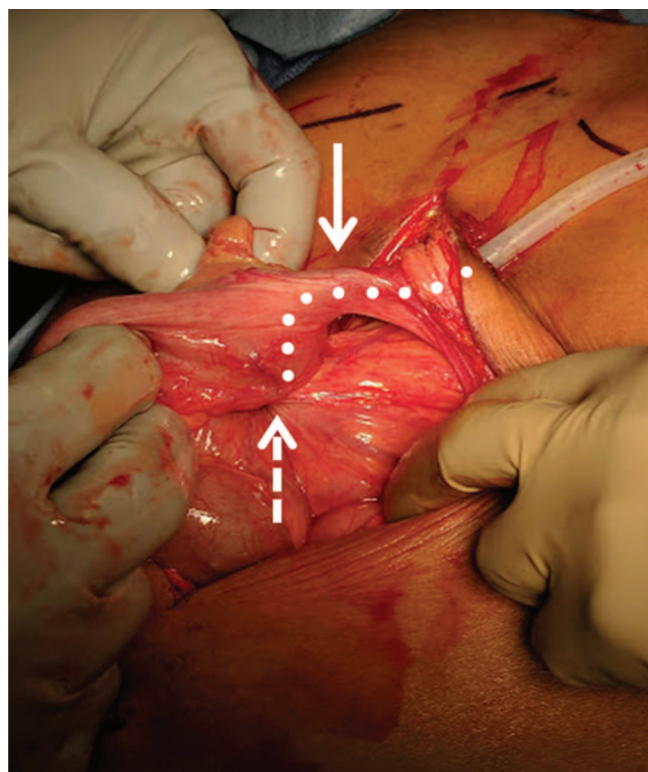


Figure 2. Exploratory laparotomy revealed a gastrocolocutaneous fistula (solid white arrow and dotted line) via the sigmoid colon into the stomach. Perforation occurred at the exit site of the sigmoid colon adjacent to the anterior gastric wall (dotted white arrow).

rapidly become the preferred method over radiologic and surgically placed g-tubes for securing durable access for enteral nutrition. Although generally considered to be a very safe procedure, multiple case series suggest that complications ranging in severity from minor to major (**Table 1**) occur at rates between 9% and 17%.^{11,12} GCCF,

Table I
PEG Tube Complications

Major	Minor
Intestinal perforation	Surgical site infection
Bleeding	Pneumoperitoneum
Abdominal organ injury	Tube dislodgement
Aspiration pneumonia	Tube clogging
Buried bumper syndrome	Peristomal granuloma
Tumor seeding	
Intestinal volvulus	
Necrotizing fasciitis	

whereby the gastrostomy tube is placed from the anterior abdominal wall, through the colon and into the stomach, is a known rare, but major, complication of PEG placement that is estimated to occur in 0.2%–0.76% of adult^{13–15} and 2%–3.5% of pediatric patients.^{16,17} GCCF can have devastating effects; however, the symptoms and time of presentation vary widely. Although colonic perforation with peritonitis in the immediate postoperative period has been described as a complication of PEG placement,¹⁸ in GCCF the fistulous tract, which adheres the anterior wall of the stomach to the colon and the colon to the abdominal wall, frequently prevents periprocedural leakage of intraluminal contents into the abdominal cavity. As a result, a malpositioned PEG tube can go unnoticed for weeks and even years.^{11,19} In fact, GCCF are often asymptomatic until the bumper of the feeding tube erodes from the lumen of the stomach into the colon, leaving a direct communication between the two hollow viscera by which gastric contents can directly enter the large bowel and vice versa. It is this communication that leads to the most common presentation of GCCF: profuse diarrhea with enteral feeds and feculent emesis.^{6,13,20,21} Other symptoms include weight loss, abdominal pain, intestinal obstruction, and difficulty in tube exchange. Although some patients will remain entirely asymptomatic,^{16,19,22} these complications can be fatal if not addressed^{21,23} and highlight the importance of identifying a GCCF if suspected. To the best of our knowledge, this case is the first in which a GCCF has presented as a delayed colonic perforation. Varying treatments for GCCF have been documented in case reports and are largely determined by the symptoms induced by the fistula itself. Uncomplicated GCCF without peritonitis or abscess can often be managed nonoperatively with removal of the gastrostomy tube and bowel rest^{24,25} In cases such as ours, however, that are complicated by frank perforation, peritonitis and/or abscess,

surgical management including laparotomy with lysis of adhesions, excision of the colocutaneous fistulous tract and/or excision of the diseased portion of bowel^{13,24} is often required. In recent years, an endoscopic over-the-scope clip system has been successfully employed to close the gastric or colonic orifices of a fistulous tract with the simultaneous endoscopic removal of the PEG tube;^{5,26} however, this requires that the tract be relatively small and there is not extensive concomitant extraluminal pathology.

A thorough understanding of gastrointestinal anatomy and proper technique during PEG tube placement are imperative for minimizing the risk of GCCF. Notably, the use of good transillumination and the direct visualization of finger indentation upon the anterior aspect of the stomach during needle localization are critical for avoiding this complication. Further, in order to safeguard against instrumenting the colon prior to entering the stomach, the guide needle should be attached to a fluid-filled syringe and continuous back pressure should be applied as the needle is advanced to ensure there is no aspiration of stool or air prior to its tip being visualized in the gastric lumen. Additionally, adequate insufflation must be used during the procedure to displace the transverse colon, which lies anterior to the stomach, from the line of instrumentation without overinsufflating the stomach. Overinsufflation can rotate the greater curvature of the stomach forward, displacing the gastrocolic omentum and the associated transverse colon anteriorly and in the line of needle trajectory.^{17,24,27} In complicated cases, such as patients with prior abdominal surgery with associated adhesive disease and distorted anatomy, one might consider performing simultaneous laparoscopy to help confirm that the needle is not introduced into the colon.²⁴

In cases where GCCF is suspected, diagnosis is best made by fistulogram with gastrografin contrast.¹³ Other imaging modalities that can be used as adjuncts include contrast tomography (CT) with water soluble contrast, barium enema, and direct visualization of the fistula via upper or lower endoscopy.^{5,8,28,29}

In summary, although rare, GCCF after PEG placement can cause significant morbidity, including delayed bowel perforation and sepsis. Attention should be paid during PEG placement to minimize risk of instrumenting the colon and imaging should be conducted if there is any suspicion that the feeding tube is passing through the bowel. Treatment will depend on the patient's symptoms but can range from nonoperative management, endoscopic fistulotomy, to exploratory surgery.

References:

1. Gauderer MW, Ponsky JL, Izant RJ Jr. Gastrostomy without laparotomy: a percutaneous endoscopic technique. *J Pediatr Surg*. 1980;15(6):872–875.
2. Wollman B, D'Agostino HB, Walus-Wigle JR, Easter DW, Beale A. Radiologic, endoscopic, and surgical gastrostomy: an institutional evaluation and meta-analysis of the literature. *Radiology*. 1995;197(3):699–704.
3. Lucendo AJ, Frigal-Ruiz AB. Percutaneous endoscopic gastrostomy: an update on its indications, management, complications, and care. *Rev Esp Enferm Dig*. 2014;106(8):529–539.
4. Strijbos D, Keszthelyi D, Bogie RMM, et al. A systematic review and meta-analysis on outcomes and complications of percutaneous endoscopic versus radiologic gastrostomy for enteral feeding. *J Clin Gastroenterol*. 2018;52(9):753–764.
5. Kim HS, Bang CS, Kim YS, et al. Two cases of gastrocolocutaneous fistula with a long asymptomatic period after percutaneous endoscopic gastrostomy. *Intest Res*. 2014;12(3):251–255.
6. Kuriyama A. Gastrocolocutaneous fistula due to percutaneous endoscopic gastrostomy placement. *Intern Med*. 2016;55(23):3549.
7. Roozrokh HC, Ripepi A, Stahlfeld K. Gastrocolocutaneous Fistula as a complication of peg tube placement. *Surg Endosc*. 2002;16(3):538–539.
8. Bertolini R, Meyenberger C, Sulz MC. First report of colonoscopic closure of a gastrocolocutaneous PEG migration with over-the-scope-clip-system. *World J Gastroenterol*. 2014;20(32):11439–11442.
9. Okutani D, Kotani K, Makihara S. A case of gastrocolocutaneous fistula as a complication of percutaneous endoscopic gastrostomy. *Acta Med Okayama*. 2008;62(2):135–8.
10. Gauderer MW. Percutaneous endoscopic gastrostomy—20 years later: a historical perspective. *J Pediatr Surg*. 2001;36(1):217–219.
11. DiSario JA. Endoscopic approaches to enteral nutritional support. *Best Pract Res Clin Gastroenterol*. 2006;20(3):605–630.
12. Lin HS, Ibrahim HZ, Kheng JW, Fee WE, Terris DJ. Percutaneous endoscopic gastrostomy: strategies for prevention and management of complications. *Laryngoscope*. 2001;111(10):1847–1852.
13. Lohiya, GS, Tan-Figueroa L, Krishna V. Intermittent diarrhea as a delayed presentation of percutaneous endoscopic gastrostomy (PEG)- associated fistula. *J Am Board Fam Med*. 2010;23(5):681–684.
14. Friedmann R, Feldman H, Sonnenblick M. Misplacement of percutaneously inserted gastrostomy tube into the colon: report of 6 cases and review of the literature. *JPEN J Parenter Enteral Nutr*. 2007;31(6):469–476.
15. Okutani D, Kotani K, Makihara S. A case of gastrocolocutaneous fistula as a complication of percutaneous endoscopic gastrostomy. *Acta Med Okayama*. 2008;62(2):135–138.
16. Patwardhan N, McHugh K, Drake D, Spitz L. Gastroenteric fistula complicating percutaneous endoscopic gastrostomy. *J Pediatr Surg*. 2004;39(4):561–564.
17. Khatak IU, Kimber C, Kiely EM, Spitz L. Percutaneous endoscopic gastrostomy in paediatric practice: complications and outcome. *J Pediatr Surg*. 1998;33(1):67–72.
18. Guloglu R, Taviloglu K, Alimoglu O. Colon injury following percutaneous endoscopic gastrostomy tube insertion. *J Laparoendosc Adv Surg Tech A*. 2003;13(1):69–72.
19. Pitsinis V, Roberts P. Gastrocolic fistula as a complication of percutaneous endoscopic gastrostomy. *EJCN*. 2003;57(7):876–878.
20. Smyth GP, McGreal GT, McDermott EW. Delayed presentation of a gastric colcutaneous fistula after percutaneous endoscopic gastrostomy. *Nutrition*. 2003;19(10):905–906.
21. Joo YJ, Koo JH, Song SH. Gastrocolic fistula as a cause of persistent diarrhea in a patient with a gastrostomy tube. *Arch Phys Med Rehabil*. 2010;91(11):1790–1792.
22. Cheung SW. A silent and chronic complication of percutaneous endoscopic gastrostomy tube: small bowel enterocutaneous fistula. *Case Rep Gastrointest Med*. 2016;1–3.
23. Holder TM, Leape LL, Ashcraft KW. Gastrostomy: its use and dangers in pediatric patients. *N Engl J Med*. 1972;286(25):1345–1347.
24. Schrag SP, Sharma R, Jaik NP, et al. Complications related to percutaneous endoscopic gastrostomy (PEG) tubes. A comprehensive clinical review. *J Gastrointest Liver Dis*. 2007;16(4):407–418.
25. Schapiro GD, Edmundowicz SA. Complications of percutaneous endoscopic gastrostomy. *Gastrointest Endosc Clin North Am*. 1996;6:409–422.
26. Gunji SS, Katayama H, Morikawa S. Successful treatment of an iatrogenic gastro-colo-cutaneous fistula in a patient with Chilaiiditi syndrome: a case report. *Cogent Med*. 2017;4:1331600.
27. Croaker GD, Najmaldin AS. Laparoscopically assisted percutaneous endoscopic gastrostomy. *Pediatr Surg Int*. 1997;12:130–131.
28. Milanchi S, Wilson M. Malposition of percutaneous endoscopic-guided gastrostomy: Guideline and management. *J Minim Access Surg*. 2008;4(1):1–4.
29. Tominaga K, Saigusa Y, Ito S, Hirahata K, Nemoto Y, Maetani I. Percutaneous endoscopic gastrostomy with the aid of a colonoscope to avoid gastrocolic fistula formation. *Endoscopy*. 2007;39(Suppl 1):E112–E113.