

Magnetic Robot–Assisted Single-Incision Cholecystectomy

Alfredo Daniel Guerron, MD, Camila Belen Ortega, MD, Chan Park, MD, Dana Portenier, MD

Department of Surgery, Duke University Health System, Durham, North Carolina, USA (all authors).

ABSTRACT

Introduction: Single-incision techniques limit triangulation, surgeon mobility, and organ visualization. The use of robot-assisted platforms has addressed several of these difficulties; however, it has also generated new challenges. To overcome these problems, we used a magnetic organ-retraction system recently approved by the U. S. Food and Drug Administration. In the present study, we report the first single-incision cholecystectomy performed combining magnetic and robotic technologies.

Case Description: The patient was a 48-year-old woman (BMI, 33 kg/m²) with cholelithiasis, who was scheduled for elective cholecystectomy with a single-incision magnetic robot-assisted procedure. The total procedure took 89 minutes (including docking); operative time was 58 minutes, where magnetic coupling was 51 minutes. Estimated blood loss was minimal. There were no complications. The patient was discharged home on the same day and was entirely satisfied with the surgery results.

Conclusion: The combination of these technologies is feasible and simplifies single-incision techniques.

Key Words: Cholecystectomy, Innovation, Magnetic surgery, Robotic surgery, Single incision.

Citation Guerron AD, Ortega CB, Park C, Portenier D. Magnetic robot–assisted single-incision cholecystectomy. CRSLS e2017.00073. DOI: 10.4293/CRSLS.2017.00073.

Copyright © 2018 by SLS, Society of Laparoendoscopic Surgeons. This is an open-access article distributed under the terms of the Creative Commons Attribution-Noncommercial-ShareAlike 3.0 Unported license, which permits unrestricted noncommercial use, distribution, and reproduction in any medium, provided the original author and source are credited.

Disclosures: Dr. Portenier is a consultant for Medtronic/Covidien (Minneapolis, Minnesota, USA), Teleflex (Wayne, Pennsylvania, USA), W. L. Gore (Newark, Delaware, USA), Allergan (Irvine, California, USA), and Intuitive (Sunnyvale, California, USA) and holds a grant from Teleflex. Dr. Park is a consultant for Medtronic, Teleflex, Phycient (Durham, North Carolina, USA) and W. L. Gore, and he holds a research grant from Teleflex. Drs Guerron and Ortega declare that they have no conflict of interest.

Address correspondence to: Alfredo D. Guerron, MD, Department of Surgery, Duke University Health System, 407 Crutchfield St, Durham, NC, 27704. Phone: 919-470-7033, Fax: 919-470-7045, E-mail: daniel.guerron@duke.edu

INTRODUCTION

Since the performance of the first laparoscopic cholecystectomy in the late 1980s, several techniques have been devised by the surgical community to keep searching for improved outcomes, fewer complications, and improved patient satisfaction. For many patients, the final appearance of the resulting scar represents a very important determining factor that correlates with their overall satisfaction with the surgical experience.¹ The demand for better cosmetic results after surgical procedures has led to an increased interest in single-incision surgery. Even though it is very attractive from the patient's standpoint, single-incision techniques present challenges during surgery.^{2–4} Instruments enter the abdomen in a parallel way

through the single port, resulting in the loss of triangulation and a severe impairment in the surgeon's mobility.⁵ In addition, the parallel approach and the resulting lack of space between instruments impair visualization and cause collisions between the instruments and the camera. It also compromises the ability to mobilize the target anatomy, resulting in suboptimal tissue exposure and increasing the time and the risk of the procedure.⁶ These difficulties have been overcome partially by the use of robotic platforms. However, limited triangulation, collision of external arms, and static retraction by the assistant's instrument still presents challenges and difficulties with the current technique.^{7,8}

Recently, a novel magnetic surgical system was developed by Levita Magnetix Corp. (San Mateo, California, USA),

and has been cleared for commercial use by the U.S. Food and Drug Administration (FDA). This unique technology helps overcome the problems described in the transition to techniques involving fewer ports. The system comprises an external magnet and a grasper with a detachable grasper tip and handle. The magnetic grasper assembly delivers and applies the detachable grasper tip to the gallbladder. Gently squeezing the handle causes the internal mechanism to release the detachable tip. The handle is then removed, leaving the introduction port available for use by another procedural instrument. With the detachable grasper tip secured to the organ, the external magnet is placed over the abdominal wall and a magnetic attraction is achieved with the detachable tip. The external magnet can then be freely moved, facilitating unconstrained shaftless tissue retraction and mobilization. Under direct visualization, the desired retraction of the gallbladder can be obtained by mobilizing the external magnet.⁹ The use of this novel device has been successful in a prospective clinical trial performed by Rivas et al and in a series of cases reported by Haskins et al.¹⁰ These clinical studies showed the safety and the feasibility of magnetic surgery in a cholecystectomy performed with a reduced (3-port)-incision technique.

This is the first report of a single-incision surgery where magnetic and robotic technologies have been combined, to have the best technologies available to improve the cholecystectomy procedure.

MATERIALS AND METHODS

The patient was a 48-year-old woman with a BMI of 33 kg/m², who presented to our clinic with postprandial pain for about a year with exacerbations that prompted visits to the emergency department for pain control. An ultrasound test revealed cholelithiasis with normal common bile duct, without any other abnormality in the laboratory data. The patient was counseled to undergo an elective cholecystectomy. The alternatives risks and benefits were discussed in detail with the patient who gave her consent to proceed with a single-incision magnetic robot-assisted cholecystectomy.

The case was completed with a single incision and the assistance of a magnetic device and a robotic platform (Da Vinci system Xi; Intuitive Surgical, Sunnyvale, California, USA). In brief, an initial incision was made in the umbilicus and deepened down to the fascia. The abdominal cavity was entered through a 2-cm incision, a figure-of-eight 1-0 Polysorb stay suture (Medtronic, Minneapolis, Minnesota, USA) was placed, and a single-incision laparos-

copy port (Da Vinci-Single Site port with curve cannulae, Intuitive Surgical) inserted. Pneumoperitoneum was established at a pressure of 15 mm Hg. Initial laparoscopic exploration revealed omental adhesions to the gallbladder only.

The magnetic surgical grasper was inserted through the single-incision assistant port, the detachable grasper tip was attached to the fundus of the gallbladder (**Figure 1A**). With the detachable grasper tip secured to the fundus of the gallbladder, the external magnet was placed over the skin of the abdominal wall and a magnetic attraction was obtained (**Figure 2, a**). This facilitated unconstrained shaftless tissue retraction and mobilization directed towards the right shoulder, thus elevating the gallbladder fundus (**Figure 1B, C**). At this point, the DaVinci system was docked with single-incision platform instruments (**Figure 2, b**). The use of magnetic retraction reduced the collision of the robotic camera and instruments during the procedure. The infundibulum was retracted laterally to expose the cystic artery and duct. The assistant, under the direction of the surgeon sitting at the console, was able to mobilize the external magnet and change the internal magnet to the desired position to achieve adequate exposure. There was no interference between the external magnet and the arms of the Da Vinci system. The surgeon was able to move the robotic instruments without any impediment or restriction. Blunt and electrocautery dissection was used to skeletonize both structures and to achieve a critical field of view by following the SAGES Safe Cholecystectomy Program.¹¹ The cystic duct and artery were clipped with Hem-o-Loc Endoclips (Teleflex, Wayne, Pennsylvania, USA) and divided with scissors. Electrocautery was used to completely detach the gall bladder from the liver. Spot fulguration was used to achieve satisfactory hemostasis. There was no puncturing of the gallbladder and no evidence of injury of any surrounding structure. The specimen with the magnetic device tip was placed in an Endocatch bag (Medtronic). The single-incision port was removed in conjunction with the Endocatch bag. The DaVinci system was undocked, and the fascia was approximated with 1-0 absorbable mono-

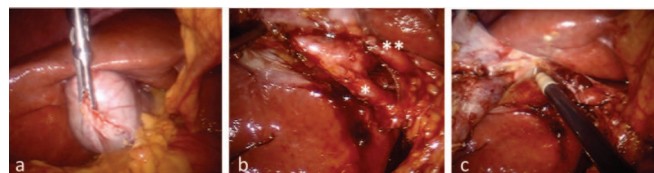


Figure 1. (A) Detachable grasper tip attached to the fundus of the gallbladder. (B) *Cystic duct; **cystic Artery. (C) Dissection of the gallbladder.

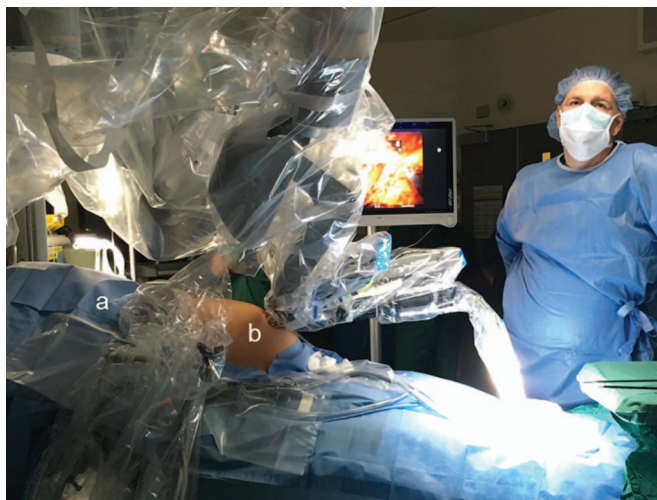


Figure 2. External magnet placed over the skin of the right upper quadrant abdominal wall (a); single port and robotic arms (b).

filament sutures from either end of the incision and tied in the middle. The skin incision was closed with 4-0 absorbable braided sutures with a subcuticular technique finished with skin glue.

Compliance With Ethical Standards

All procedures were in accordance with the ethical standards of the institutional and national research committees and with the 1964 Declaration of Helsinki and its later amendments or comparable ethical standards. Informed consent was obtained from all individual participants included in the study.

RESULTS

The procedure was completed through a single incision, without using any accessory port or additional instrument for retraction. The estimated blood loss was less than 10 mL. The total procedure took 89 minutes (including docking), operative time was 58 minutes wherein the magnetic coupling was 51 min. There were no complications related to the magnetic device or the procedure. The patient was discharged home after recovery the same day.

On the next postoperative day, the patient reported no recurrence of previous symptoms, tolerated a regular diet, and ambulated without difficulty. She stopped the consumption of oral pain medication 3 d after the procedure. During follow-up (postoperative week 3), the patient was entirely satisfied with the results of the surgery, in particular with the nonvisible incision.

DISCUSSION

We describe a magnetic robotic single-incision cholecystectomy. Since the first report of single-incision robot-assisted cholecystectomy, there have been a myriad of reports advocating or opposing robot-assisted platforms.¹² Single-port robotic assistance is becoming popular for potentially improved outcomes, which may include fewer incisions, improved cosmesis resulting in higher patient satisfaction, and shorter recovery time. From a surgical perspective, it can result in easier visualization, more precision, and decreased risk of injuring nearby structures.^{9,13}

Difficulties reported on single-incision surgery have been partially solved with the creation of a robot-assisted platform that included the use of a multichannel access port with room for 4 cannulae and an insufflation valve. Two curved cannulae are for robotically controlled instruments. The curved cannulae are integral to the system because their configuration allows the instruments to be positioned to achieve triangulation of the target anatomy. This triangulation is achieved by crossing the curved cannulae midway through the access port. The great advantage of the robotic system, is the capability to link the right hand of the surgeon with the left crossed instrument (and vice versa for the other side), eliminating the “mirror” effect that increases difficulty when crossing the instruments. Nevertheless, a grasper through the assistant port is needed to retract the fundus of the gallbladder, instrument that creates great interference in the surgical field and constant collision with the camera and the two other instruments. Furthermore, this clashing causes great impairment, as all the instruments are moved in a block configuration. This is the reason that the robotic platform is a partial solution for the challenges of single-incision surgery.

Magnetic surgery delivers a shaftless retraction providing the advantage of restoring triangulation without obstructing the surgical field. Because of its shaftless nature, the device increases the working space between the camera and instruments, thus decreasing instrument collision. In addition, the unconstrained nature of the magnetic retraction permits dynamic repositioning of the grasper to optimize organ retraction, as well as liberating the assistant access port and therefore enabling the use of an extra instrument, if needed. The magnetic surgical system facilitates tissue grasping while improving the visualization in a single-incision environment, thus enhancing the safety of the critical view.

There are a few limitations of the magnetic surgery system. Similar to any newly introduced technology, the

surgical team requires training and practice which involves investment of time and resources. The system is not suitable for use in patients with large livers or an extremely high BMI; the characteristic body habitus of these patients would decrease attraction in the magnetic field. Furthermore, the use is contraindicated for patients with pacemakers and metallic implants. We acknowledge that another downside of this technology is the initial extra direct cost of the procedure, but we consider that with a long-term increase in case volume and technology implementation, a balanced cost-benefit will be achieved.

Detractors of the single-incision laparoscopic surgery express this technology may add little to the traditional laparoscopic technique, whereas supporters believe it offers value to patients. Certainly, there are patients who show great interest in reduced scar techniques, such as the willingness to change hospitals and pay a higher financial contribution for a procedure with less scarring.¹⁴

Although the additional direct cost of use of new technology in cholecystectomy may not seem necessary at this stage, surgeons have to be open minded to evaluate and challenge the current status quo of the current techniques.^{15–17} Incremental cost has to be evaluated against patient benefits, satisfaction, and overall savings in the complete surgical process, considering the savings in complications, hospital stays, and recovery time.

CONCLUSION

The combination of these 2 technologies is feasible and enables simplifying single-incision techniques. Patient satisfaction should be the goal that directs innovation in the next stages of evolution of surgical practice.

References:

1. Park SK, Olweny EO, Best SL, Tracy CR, Mir SA, Cadeddu JA. Patient-reported body image and cosmesis outcomes following kidney surgery: comparison of laparoendoscopic single-site, laparoscopic, and open surgery. *Eur Urol*. 2011;60:1097–1104.
2. Marks JM, Phillips MS, Tacchino R, et al. Single-incision laparoscopic cholecystectomy is associated with improved cosmesis scoring at the cost of significantly higher hernia rates: 1-year results of a prospective randomized, multicenter, single-blinded trial of traditional multiport laparoscopic cholecystectomy vs single-incision laparoscopic cholecystectomy. *J Am Coll Surg*. 2013;216:1039–1047.
3. Mutter D, Callari C, Diana M, Dallemagne B, Leroy J, Marsaux J. Single port laparoscopic cholecystectomy: which technique, which surgeon, for which patient? A study of the implementation in a teaching hospital. *J Hepatobiliary Pancreat Sci*. 2011;18:453–457.
4. Prasad A, Mukherjee KA, Kaul S, Kaur M. Postoperative pain after cholecystectomy: conventional laparoscopy versus single-incision laparoscopic surgery. *J Minim Access Surg*. 2011;7:24–27.
5. Rivas H, Varela E, Scott D. Single-incision laparoscopic cholecystectomy: initial evaluation of a large series of patients. *Surg Endosc*. 2010;24:1403–1412.
6. Wren SM, Curet MJ. Single-port robotic cholecystectomy: results from a first human use clinical study of the new da Vinci single-site surgical platform. *Arch Surg*. 2011;146:1122–1127.
7. Morel P, Hagen ME, Bucher P, Buchs NC, Pugin F. Robotic single-port cholecystectomy using a new platform: initial clinical experience. *J Gastrointest Surg*. 2011;15:2182–2186.
8. Buzad FA, Corne LM, Brown TC, et al. Single-site robotic cholecystectomy: efficiency and cost analysis. *Int J Med Robot*. 2013;9:365–370.
9. Rivas H, Robles I, Riquelme F, et al. Magnetic surgery: results from first prospective clinical trial in 50 patients. *Ann Surg*. In press, 2017.
10. Haskins IN, Strong AT, Allemang MT, Bencsath KP, Rodriguez JH, Kroh MD. Magnetic surgery: first U.S. experience with a novel device. *Surg Endosc*. In press, 2017.
11. Society of America Gastrointestinal and Endoscopic Surgeons. <http://www.sages.org/safe-cholecystectomy-program/>. Accessed October 27, 2017.
12. Kroh M, El-Hayek K, Rosenblatt S, et al. First human surgery with a novel single-port robotic system: cholecystectomy using the da Vinci Single-Site platform. *Surg Endosc*. 2011;25:3566–3573.
13. Kudsi OY, Castellanos A, Kaza S, et al. Cosmesis, patient satisfaction, and quality of life after da Vinci Single-Site cholecystectomy and multiport laparoscopic cholecystectomy: short-term results from a prospective, multicenter, randomized, controlled trial. *Surg Endosc*. 2016;31:3242–3250.
14. Fransen SA, Broeders E, Stassen L, Bouvy N. The voice of Holland: Dutch public and patient's opinion favours single-port laparoscopy. *J Minim Access Surg*. 2014;10:119–125.
15. Ponsky JL. Are we making progress? Robotic single-incision laparoscopic surgery. *Arch Surg*. 2011;146:1127.
16. Kavic MS. Robotics, technology, and the future of surgery. *JSLs*. 2000;4:277–279.
17. Chung PJ, Huang R, Policastro L, et al. Single-site robotic cholecystectomy at an inner-city academic center. *JSLs*. 2015;Jul-Sep;19(3):e2015.00033.