

Type IV Mirizzi Syndrome Treated with Hepaticoduodenostomy and Minilaparoscopy

Gustavo Lopes de Carvalho, MD, PhD, Gilberto Fernandes Silva de Abreu, MD, MSc, Diego Laurentino Lima, MD, Gustavo Henrique Belarmino de Góes, Medical Student

Faculty of Medical Sciences (all authors) and University of Pernambuco (UPE), Recife, Brazil (Dr. Carvalho).

ABSTRACT

Introduction: Mirizzi syndrome (MS) is an uncommon complication of long-term chronic cholecystitis, characterized by extrinsic compression of the common hepatic duct or the presence of cholecystobiliary fistula. A case of type IV MS, with extensively damaged common hepatic duct (CHD) due to gallstone impaction and fistula, was effectively treated by minilaparoscopic hepaticoduodenostomy (HD).

Case Description: The patient was a woman, 36 years old, weighing 66 kg, and standing 1.55 m. For 3 weeks, she had been experiencing episodes of strong right-upper-quadrant pain, radiating to the back. She also presented with choloria, fecal acholia, and severe jaundice. Preoperative magnetic resonance cholangiopancreatography (MRCP) suggested the diagnosis of Mirizzi syndrome (MS). Surgery started with “dome-down” dissection of the gallbladder. The cystic duct and the CHD were found to be highly compromised close to the gallstone impacted in the infundibulum. After resection of the affected bile ducts, the biliary tract reconstruction was performed by minilaparoscopy (MINI). The patient was discharged uneventfully 6 days after surgery, without complication.

Discussion: Because of the severely compromised CHD, HD was the technique used for reconstruction, for its simple execution, and several proven advantages over hepaticojejunostomy. It was performed by MINI, a new, effective, and refined minimally invasive technique in which the surgeon uses low-friction trocars to improve visualization and dexterity in delicate surgical tasks. A Kocher maneuver was necessary to make possible this type of reconstruction.

Conclusion: There is no consensus yet about the best type of reconstruction to use for a severely damaged CHD. In the present case, HD by MINI proved to be a safe and effective method, emphasizing its known advantages.

Key Words: Biliary fistula, Biliary reconstruction, Biliary tract injury, Hepaticoduodenal anastomosis, Hepaticoduodenostomy, Hepaticojejunostomy, Microlaparoscopy, Minilaparoscopy, Mirizzi syndrome type IV, Needlescopic surgery.

Citation Carvalho GL, Silva de Abreu GF, Lima DL, Belarmino de Góes GH. Type IV mirizzi syndrome treated by hepaticoduodenostomy by minilaparoscopy. CRSLS e2016.00057. DOI: 10.4293/CRSLS.2016.00057.

Copyright © 2016 by SLS, Society of Laparoendoscopic Surgeons. This is an open-access article distributed under the terms of the Creative Commons Attribution-Noncommercial-ShareAlike 3.0 Unported license, which permits unrestricted noncommercial use, distribution, and reproduction in any medium, provided the original author and source are credited.

Disclosures: Dr. Carvalho reports nonfinancial support from Karl Storz. The remaining authors declare no conflicts of interest.

Author contributions: Drs. Carvalho and Abreu designed the study. All authors were responsible for data acquisition and analysis. Drs. Carvalho and Lima developed and edited the manuscript.

Address correspondence to: Dr. Carvalho, MD, PhD, MBA, Rua Visconde de Jequitinhonha, 1144 SL910, CEP: 51030-020 Recife, PE, BRAZIL. Telephone: +55-81-99971-9698. Fax: +55-81-2129-1910, E-mail: glcmd1@gmail.com

INTRODUCTION

Mirizzi syndrome (MS) is an uncommon complication of long-term chronic cholecystitis, usually characterized by extrinsic compression of the common hepatic duct or the presence of cholecystobiliary fistula.¹ The gallstones may

be impacted in the cystic duct or gallbladder infundibulum. This impaction may trigger an inflammatory process in the common hepatic duct, featuring another etiology of MS. Occlusion of the bile flow can also occur by compression or destruction of the wall of the common hepatic duct. The syndrome was first described by Pablo Mirizzi in

1948² and is found in between 0.05 and 2.7% of all patients undergoing surgery for gallstones.^{1,3} The main signs and symptoms, in descending sequence of prevalence are abdominal pain, jaundice, nausea and vomiting, choloria, and fever. The Mirizzi classification established by Csendes et al¹ is shown in **Figure 1**.

The successful treatment of a type IV MS with extensive destruction of the common hepatic duct (CHD) by cholecystectomy followed by a hepaticoduodenostomy (HD) fully performed by minilaparoscopy (MINI) is described herein. There are no reports in the literature regarding the use of minilaparoscopy for the treatment of type IV MS, not forgetting that the use of the chosen type of anastomosis (HD) remains controversial.

CASE DESCRIPTION

A 36-year-old woman, weighing 66 kg (145.5 lb) and standing 1.55 m (5 ft) tall, with a history of open abdominal surgery (removal of uterine cervix tumor) presented with several episodes of right upper quadrant pain radiating to the back for more than 3 weeks. She also had choloria, acholia, and a few episodes of postprandial vomiting. In her physical examination, she presented with jaundice (**Figure 2**), distended abdomen, and palpable pain in the right upper quadrant of the abdomen. Pre- and postoperative magnetic resonance cholangiopancreatography (MRCP) was performed; and representative images

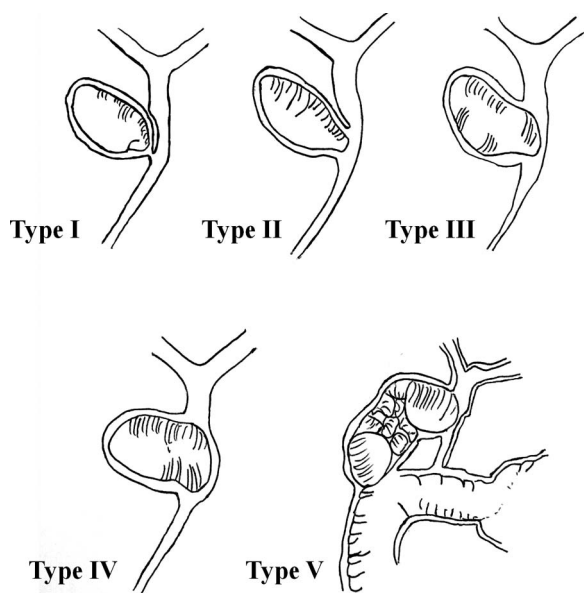


Figure 1. Schematic representation of the Csendes classification for Mirizzi syndrome (2008).¹

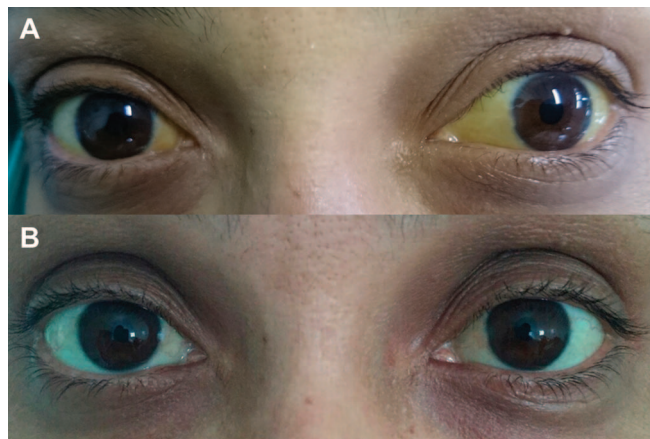


Figure 2. Close up view of patient's eyes. (A) Preoperative view of patient with severe jaundice. (B) Six days after surgery, the patient showed significant relief of jaundice.

are presented in **Figure 3**. Pre- and postoperative blood test results are summarized in **Table 1**.

Surgical Technique

Surgery was performed with the patient supine, with a cerebrosplenic slope of 30° and right rotation. Pneumoperitoneum was performed by an open technique and an 11-mm trocar was placed in the umbilicus to facilitate the use of a 10-mm, 30° optics of conventional laparoscopy. After establishing the pneumoperitoneum, 4 new low-friction atraumatic trocars of 3.5 mm were placed along the right costal border. The setting of the surgical team (**Figure 4**) and the positioning of the trocars (**Figure 5**) were according to our standard for minilaparoscopic cholecystectomy.⁴ The procedure started with the release of the gallbladder “fundus first” from the liver bed, followed by the isolation, sealing, and transection of the cystic artery by electrocautery.^{4–7} Blunt dissection of the gallbladder was performed by the “dome-down” technique (**Figure 6**), using a suction-irrigation cannula, making the surgical technique ore delicate. The gallbladder fundus was injured during its dissection, and its contents were promptly suctioned, avoiding gross contamination.

During the procedure, the cystic duct was found to have been destroyed by fibrosis in the place where the gallstone was impacted in the infundibulum. Partial resection of the destroyed CHD area was then performed (**Figure 7**).

A single gallstone (2.0 × 2.5 cm) was extracted from the damaged bile ducts (**Figure 8**) and an intraoperative

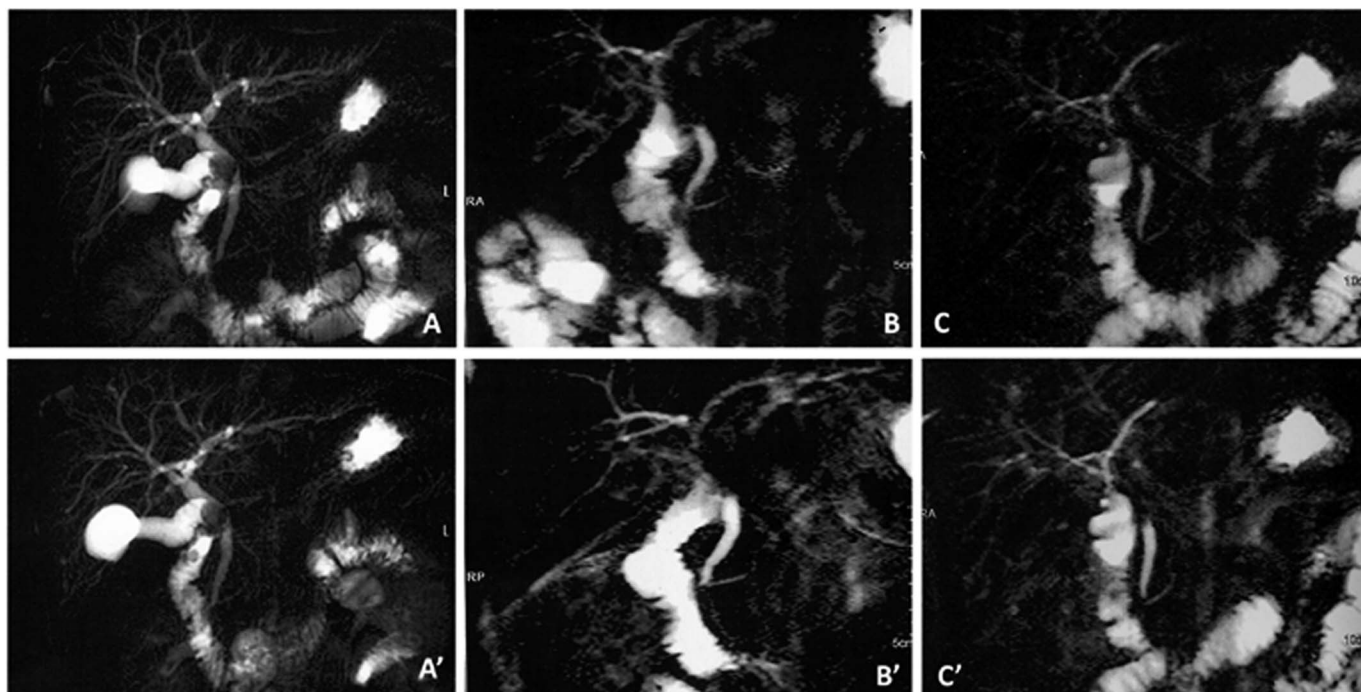


Figure 3. MRCP. **A, A'**, Before surgery: important compression of the common hepatic duct by a gallstone. **B–B'**, Fifth POD: arching the duodenum in meeting the anastomosis. **C, C'**, Fiftieth POD: HD; biliary tract with normal diameter.

Table 1.
Laboratory Tests Performed Before and After Surgery

	Before Surgery	Immediately After Surgery	Postoperative Day 15	Postoperative Month 3	Reference Values*
Alkaline phosphatase (U/L)	293.0	212.8	81.72	79.7	35–104
γ -Glutamyl transferase (mg/dl)	1306.0	797.9	330.59	51.2	8–41
Total bilirubin (mg/dl)	6.4	3.71	1.49	0.2	0.2–1.0
Conjugated bilirubin (mg/dl)	6.0	3.36	1.21	0.12	<0.2
Unconjugated bilirubin (mg/dl)	0.4	0.3	0.28	0.1	0.2–0.8
AST (U/L)	256.0	177.4	46.09	16.4	<40
ALT (U/L)	329.0	288.3	173.26	16.4	<31

*Reference values for women aged over 20 years.

cholangiography was attempted by inserting an 8-French catheter into the ruptured CHD (**Figure 9**). However, all 3 attempts were unsuccessful because of operational reasons (all X-ray machines failed).

The cystic duct, common bile duct, and common hepatic duct were also found partially destroyed, and the bile flow was totally obstructed because of stone impaction and fibrosis in the exact location where the gallstone was located in the infundibulum (**Figure 10**).

An extensive Kocher maneuver was performed allowing a wide release of the duodenum (**Figure 11**), and HD was performed with a 5-0 polydioxanone suture (PDS).

Because of the massive destruction of the main bile ducts and the cystic duct, making impossible anatomic reconstruction of the biliary tract, HD by minilaparoscopy (MINI) was the technique selected for reconstruction.

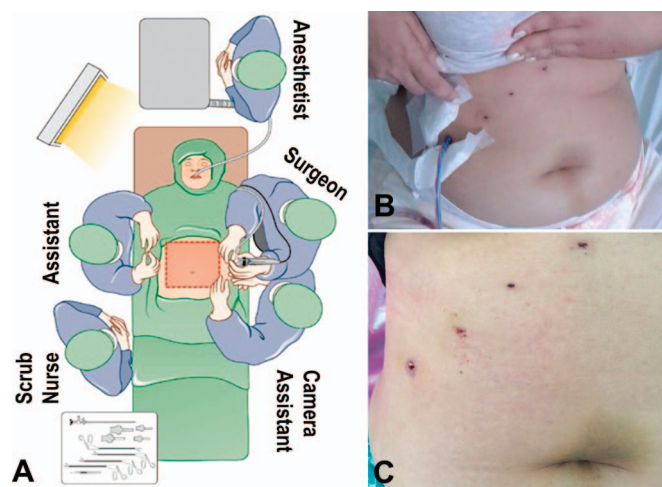


Figure 4. A, Operating room organization and the surgical team. B, Surgical wounds showing positioning of the port sites. Four 3.5-mm trocars were used along the right costal margin and 1 of 11 mm in the umbilicus for the use of a 10-mm scope of conventional laparoscopy. C, Except for the drain exit, minimal scars were observed after 6 days.

After the bile duct reconstruction, to check anastomosis, a Levine gastric tube was inserted in the stomach by oral route, then a duodenal hyperinflation test was performed. No air leak was detected during the test. After enlarging the most lateral trocar access to 5 mm, through this incision, we placed a suction drainage in the subhepatic space (**Figure 4**). The approximate surgery time was 350 min. No bile leakage was detected, and the drain was removed after 72 h.

DISCUSSION

MS is an infrequent complication of long-term chronic cholecystitis, more prevalent in women. The constant compression exerted by the gallstone aggravated by the inflammation of the structures involved, can cause 2 types of fistula: between the cystic duct and the extrahepatic bile duct and between the infundibulum and the common bile duct. In the cholecystoenteric fistula, the patient can present with the clinical condition of a biliary ileus. In the cholecystobiliary fistula, the gallstone may migrate to the common bile duct or the common hepatic duct.^{1,2,8,9} Recognition of MS is important because of the high risk of

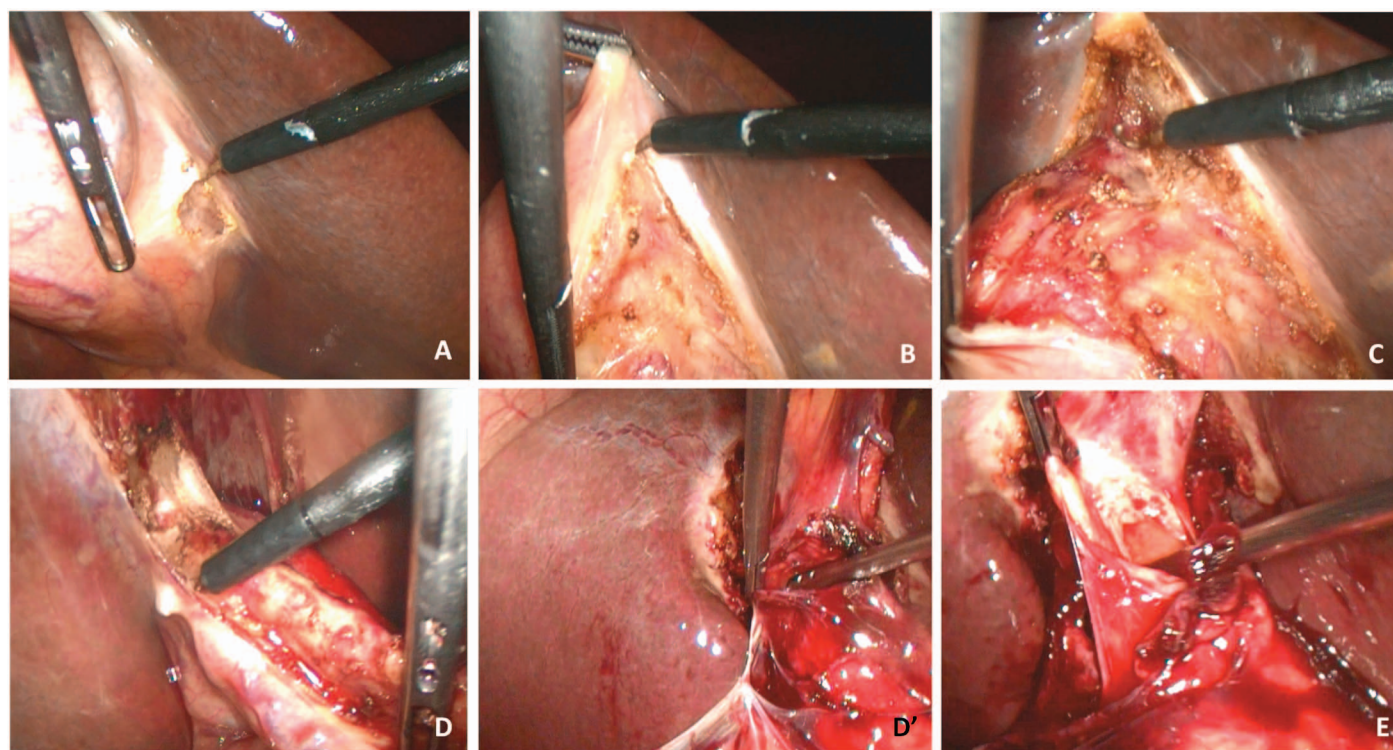


Figure 5. Anterograde cholecystectomy. A, Beginning of the dissection for the left cephalad wall. B, Progression of gallbladder removal with minilaparoscopic approach. C, Top-approach dissection. D, D', Dissection near the infundibulum. E, Infundibulum opening showing rear wall of the common bile duct.

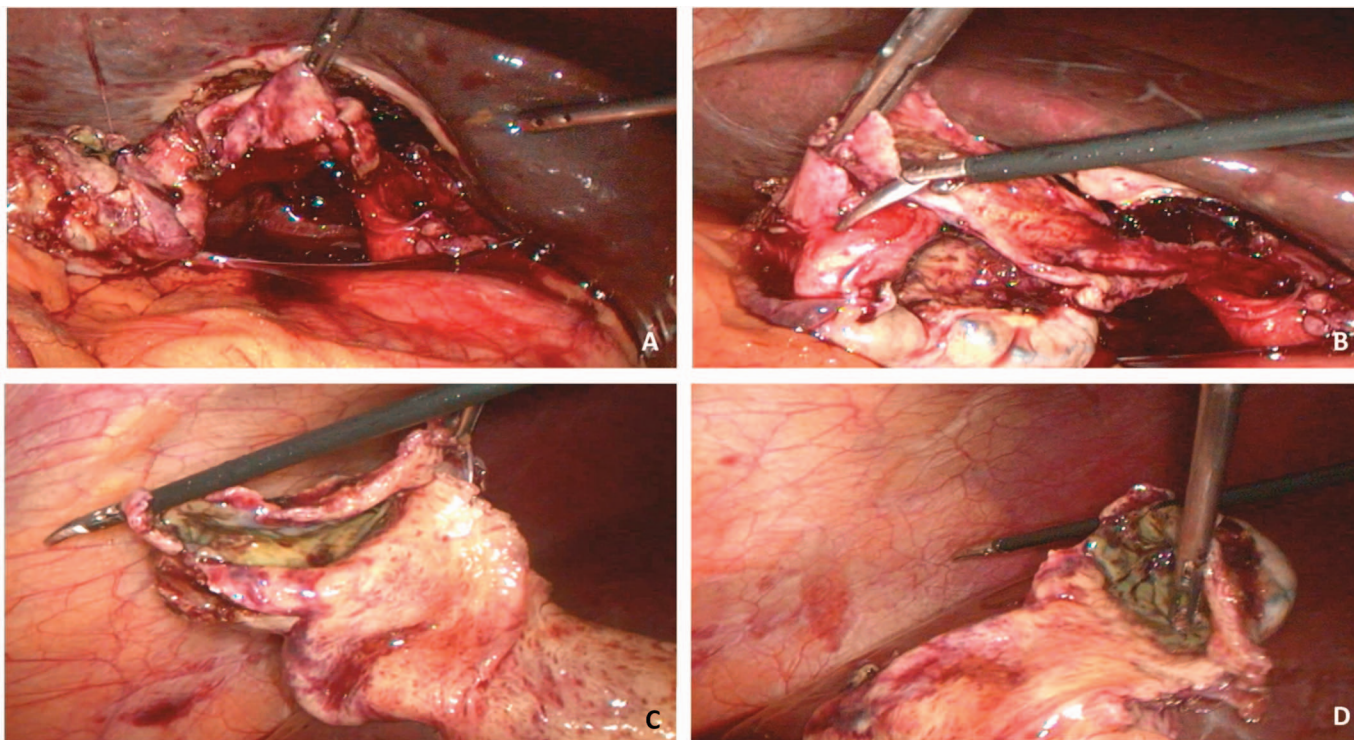


Figure 6. **A**, Gallbladder positioned to identify its limit with the main bile duct. **B**, Opening of the vesicle. It is observed with destroyed anterior wall. **C**, Gallbladder with infundibulum and cystic duct destroyed by fibrosis. **D**, Partially open vesicle with thick walls.

iatrogenic injury of the bile ducts during surgery, especially when it is difficult to establish the preoperative diagnosis.^{1,8–11}

A high surgical skill and experience in the bile duct exploration are needed to avoid iatrogenic injuries during MS surgery.^{4–7,9} Thus, treatment of minimally invasive MS is a major surgical challenge because of the intense inflammatory process, leaving the bile ducts dense, with many adhesions that distort the natural anatomy, and in some cases, creating a cholecystobiliary fistula. Excessive bleeding during the dissection of the triangle of Calot can be an important cause of iatrogenic lesion of the bile ducts.^{12–14}

There is no consensus yet in the literature on the management of MS in terms of both diagnosis and surgical treatment.¹⁵ Some authors do not consider laparoscopy as the first choice because of the intense inflammatory process caused by the disease, and some even consider it a contraindication to the minimally invasive approach. However, the procedure can be successfully performed by experienced laparoscopic hepatobiliary surgeons.^{4–7,9,13} The choice of which surgical technique to use will depend on the type of MS and the level of obstruction of the common bile

duct. Therefore, there are some alternatives that may contribute to reducing the incidence of iatrogenic injuries:

1. Anterograde cholecystectomy (“dome-down”), as in the present case, is used when approaching the gallbladder by the infundibulum is impossible or unsafe. This approach allows safe identification of both the cystic artery and the cystic duct^{4,14–18} (**Figure 5**).

2. Dissection using the tip of the irrigation–aspiration cannula allows the separation of the adhesions atraumatically, and simultaneously can be effective for aspirating any eventual bleeding^{4,15,16} (**Figure 5**).

3. Intraoperative cholangiography has a crucial role, as it can show the whole anatomy of the biliary tract, helping to prevent damage or at least promote early identification of any iatrogenic damage to the biliary tree.^{15–18}

When necessary, once the removal of the gallstones from the infundibulum is completed, the choledochal duct drainage may require a technique to avoid subsequent stasis and cholangitis. This drainage can be achieved by several techniques, such as by simply placing a Kehr drain (T tube) or performing a biliary–enteric derivation. However, note that a consensus among surgeons has not been reached, either on the technique to be used for recon-

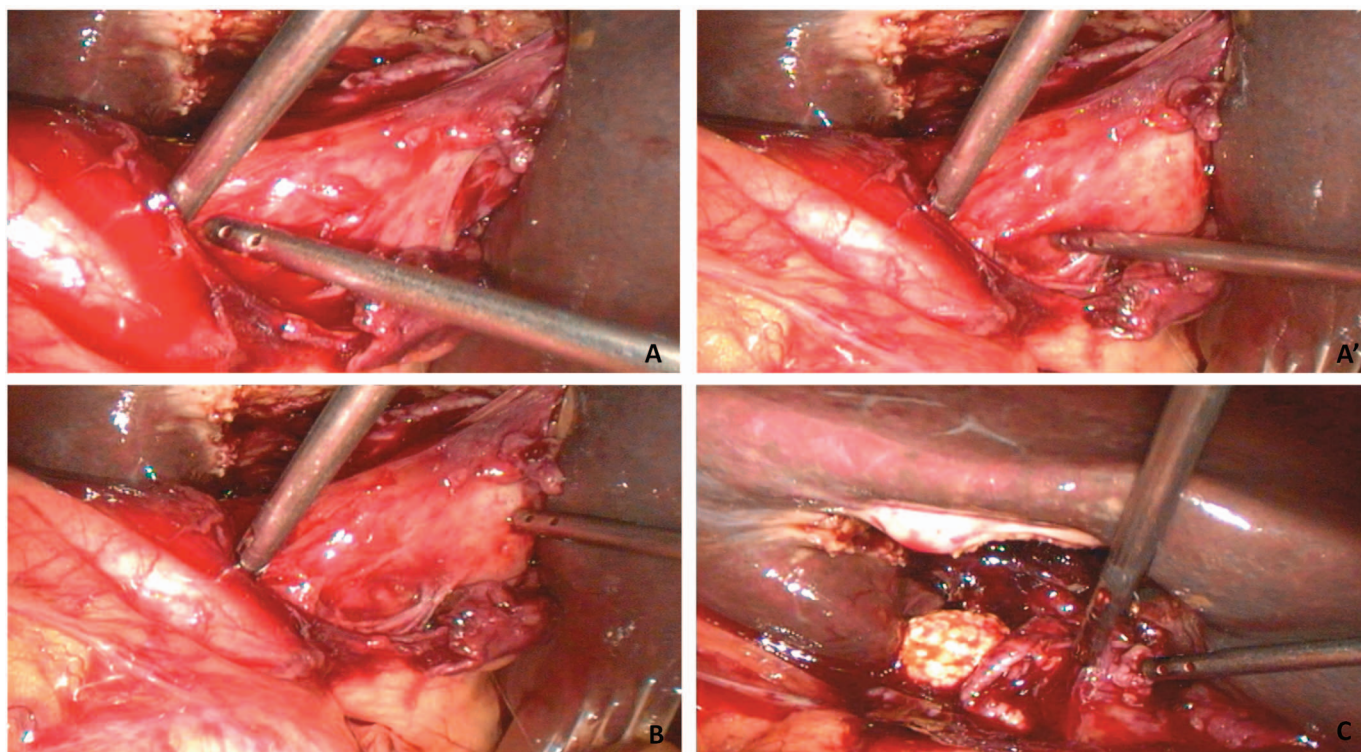


Figure 7. **A, A',** Atraumatic dissection of the biliary tract using an irrigation–aspiration cannula. **B,** Gallbladder wall dissection using irrigation–aspiration cannula to release the gallstone. **C,** Single gallstone released of the infundibulum. The front wall of the bile duct is denuded.

struction of the bile ducts or the route of access (open or laparoscopy).^{19–22}

The debate surrounding biliary reconstruction by Roux-en-Y hepaticojejunostomy (HJ) or by HD centers on the opinion that HD reconstruction is more often complicated by bile gastritis and cholangitis and is associated with a higher ongoing risk of cholangiocarcinoma.^{19,20}

Actually, HJ is the most commonly used technique, even with the claim that HD may be associated with higher post-operative complications.^{19,20} On the other hand, some surgeons consider HD to be a more physiological procedure, much simpler to perform, and associated with fewer complications, such as anastomotic leak, adhesive bowel obstruction, and peptic ulcer, when compared to HJ.^{21–23} In 1905, Mayo²⁴ reported one of the earliest successful cases of HD as a method of biliary reconstruction and was responsible for popularizing and refining the HD technique.

It is interesting to note that a retrospective cohort study also reported major complications when HJ was used for reconstruction of the biliary tract compared with HD. In addition to being more accessible endoscopically, HD has

lower stricture rates, lesser morbidity, and lower risk of bile gastritis or cholangitis than HJ.^{25–27} When comparing the 2 biliary–enteric reconstruction modalities (HD vs HJ) after choledochal cyst excision, Yeung et al²⁶ related that HD has been shown to be safe and feasible, with shortened operative time and comparable short-term postoperative outcomes to HJ reconstruction.

In an elegant study, Liem et al²⁷ examined (using a large series of patients) the efficacy and complications of laparoscopic HD after resection of a choledochal cyst. Of the 74 cases reported, there was only 1 conversion to open surgery and no deaths. Of the 74 patients, 56 were observed for 3–12 months. In these patients, cholangitis occurred in 3 and bile-reflux–related gastritis in 8. There was no jaundice. These results, therefore, corroborate to show the efficacy and safety of HD anastomosis.²⁷

In the present case, the main bile ducts were found to be almost totally destroyed by the fistula, inflammation, and fibrosis in the location where the gallstone has become impacted in the infundibulum. Therefore, cholecystectomy was performed, followed by resection of the dam-

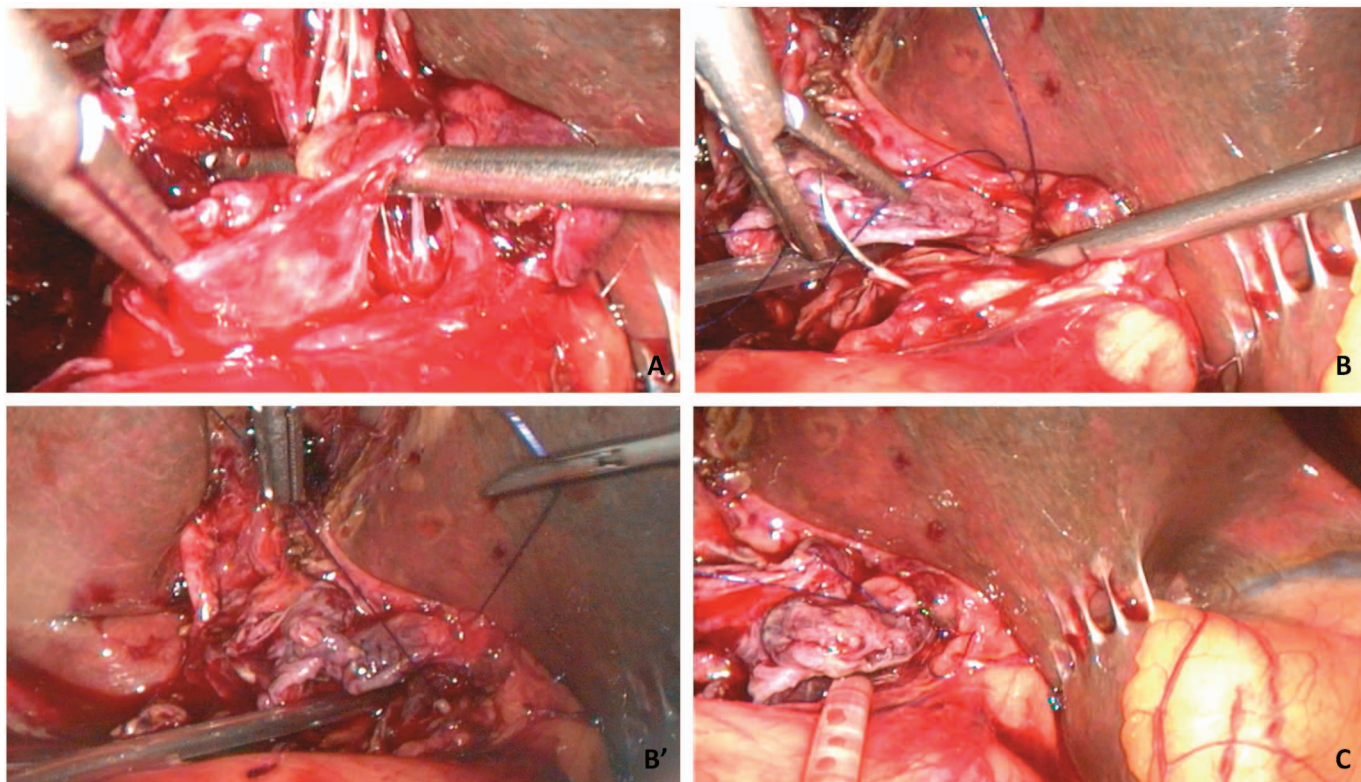


Figure 8. A, Isolation of the main bile duct to perform cholangiography. B, B', A 8-French catheter fixed in the biliary duct for the cholangiography. C, Catheterization bile hole for performing cholangiography during surgery.

aged bile ducts and HD with manual suture for the biliary tract reconstruction.

To perform the procedure by MINI was our elected choice because of our previous experience with using instruments with reduced diameter, especially in advanced and complex minimally invasive procedures. MINI has significant advantages for patients and surgeons. To patients, the obvious attractions of MINI over traditional laparoscopy seem clear—smaller incisions, less scarring, and possibly reduced postoperative pain.^{4,5,7} To surgeons, recent clinical studies have demonstrated some great advantages of minilaparoscopy in technical feasibility, safety, and effectiveness for several different procedures.⁵ For transanal endoscopic microsurgery (TEM), Araujo et al²⁹ concluded that mini-instruments provide improved visualization in this limited working space compared with conventional 5-mm instruments. Also for cholecystectomy, inguinal hernia repair, and other complex procedures that demand delicacy, MINI has shown advantages that go far beyond cosmesis: a more precise movement and a better visualization of the surgery field when a closer view is necessary.^{5,7,28–30} Furthermore, we used the

new low friction minitrocars that add even more advantages to this technique. By noticeably reducing (essentially eliminating) the friction forces between the trocar and the mini-instruments, the precisely engineered trocars result in less movement and fewer trocar dislocations from the abdominal wall, which reduces abdominal wall trauma and contributes even more to improved cosmetic results. In this particular case, minilaparoscopy added superior precision, visualization, and ability to perform delicate techniques for the complex biliary procedure.^{5,7,28–30}

The strategy chosen for the treatment of type IV MS—HD by minilaparoscopy—provided good results. On the second postoperative day (POD) the patient stopped complaining of abdominal pain, and on the third POD, choluria and acholia were absent. Jaundice was not perceived in the sixth POD (**Figure 2B**). The patient was discharged uneventfully 6 days after the procedure without further complications (**Figure 4C**). The MRC performed on the 50th POD demonstrated the HD pervious and biliary tract with normal diameter (**Figure 3C**). After

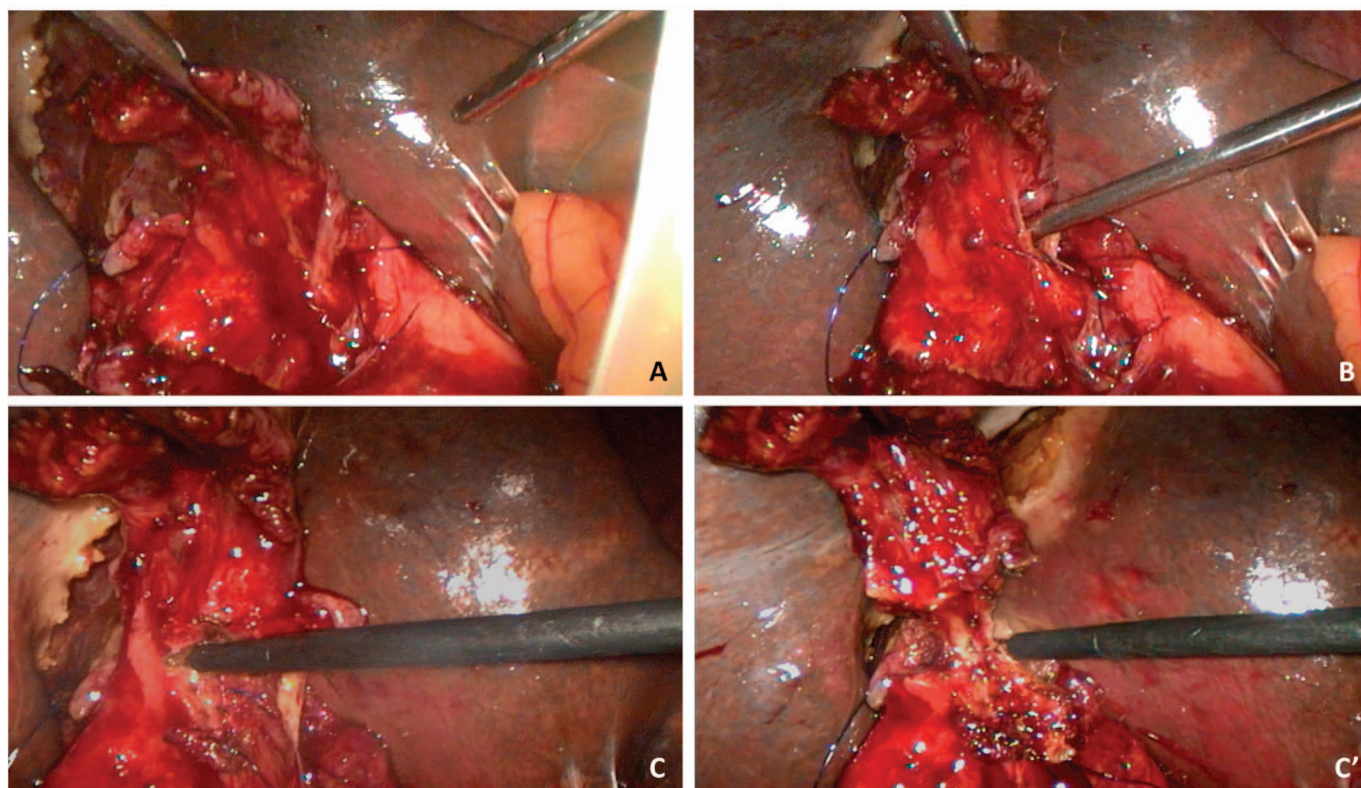


Figure 9. **A**, Bile duct with front wall destroyed and repaired for occlusion of the distal portion. **B**, Isolation of the posterior wall of the bile duct. **C, C'**, Resection of the gallbladder, separating it from the main bile duct with the Hook type electrocautery.

a 10-month follow-up, the patient remained asymptomatic and highly satisfied with the result.

CONCLUSION

This is a report of successful laparoscopic treatment of an adult patient with MS type IV. Even though there is no consensus in the literature about the ideal approach or the best type of reconstruction of a severely damaged CHD, in the present case, minilaparoscopy by HD was a safe and effective method, emphasizing its known advantages.

References:

1. Beltran MA, Csendes A, Cruces KS. The relationship of Mirizzi syndrome and cholecystoenteric fistula: validation of a modified classification. *World J Surg.* 2008;32:2237–2243.
2. Mirizzi PL. Syndrome del conducto hepatico. *J Int Chirug.* 1948;8:731–777.
3. Johnson LW, Sehon JK, Lee WC, Zibari GB, McDonald JC. Mirizzi syndrome: experience from a multi-institutional review. *Am Surg.* 2001;67:11.4.
4. Carvalho GL, Silva FW, Silva JSN, et al. Needlescopic clipless cholecystectomy as an efficient, safe, and cost-effective alternative with diminutive scars: the first 1000 cases. *Surg Laparosc Endosc Percutan Tech.* 2009;19:368–372.
5. Redan JA, Humphries AR, Farmer B, et al. “Big operations using mini instruments”: the evolution of mini laparoscopy in the surgical realm. *Surg Technol Int.* 2015;27:19–30.
6. Carvalho GL, Paquentin EM, Rao P. Should high-frequency electrosurgery be discouraged during laparoscopic surgery? *Surg Endosc.* 2016;30:401–403.
7. Carvalho GL, Loureiro MP, Bonim EA. Renaissance of mini-laparoscopy in the notes and single port era: a tale of simplicity. *JSLS.* 2011;15:585–588.
8. McSherry CK, Ferstenberg H, Vishup M. The Mirizzi syndrome: suggested classification and surgical therapy. *Surg Gastroenterol.* 1982;1:219–225.
9. Ibrarullah MD, Mishra T, Das AP. Mirizzi syndrome. *Indian J Surg.* 2008;70:281–287.
10. Fonseca Neto OCL, Pedrosa MGL, Miranda Al. Surgical management of Mirizzi syndrome (In English, Portuguese). *ABCD Arq Bras Cir Dig.* 2008;21:51–54.

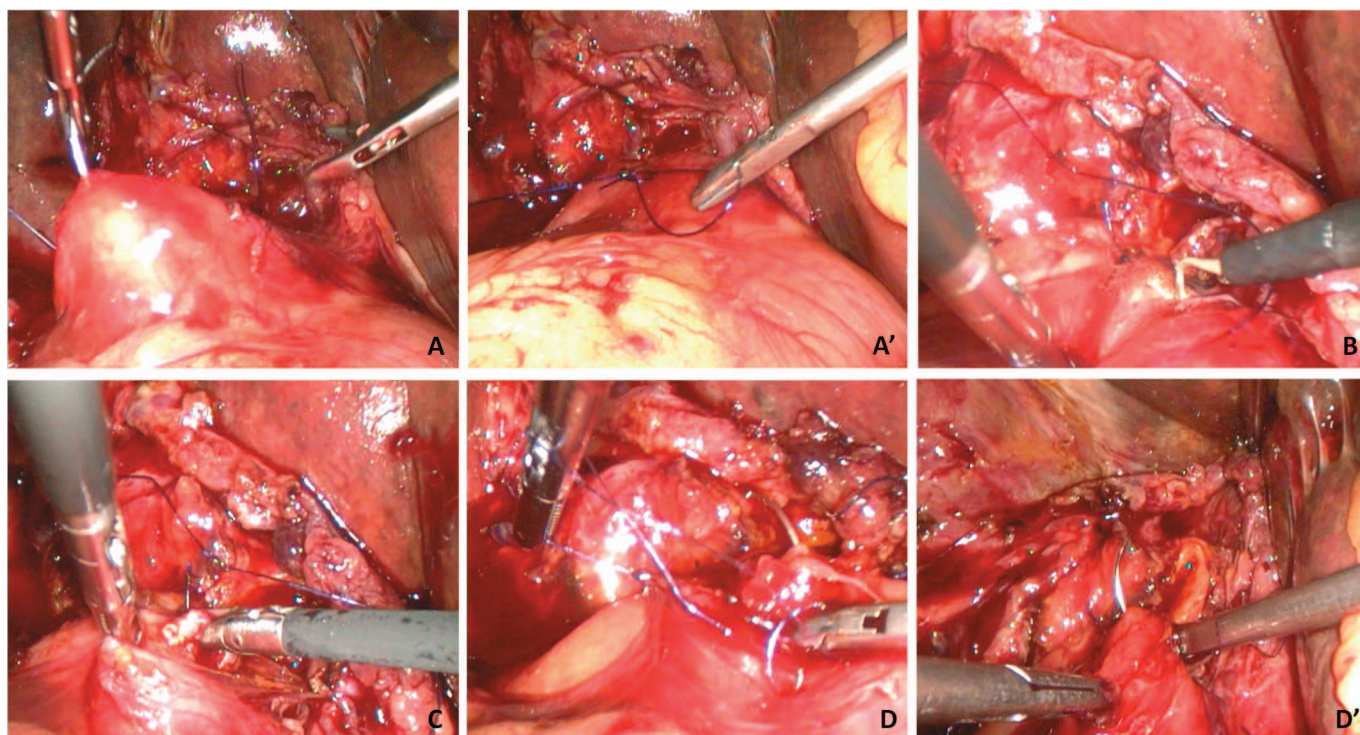


Figure 10. **A, A'**, Guidance reference point for opening the duodenum. **B**, Duodenal opening with the Hook to construct the hepatoduodenal anastomosis. **C**, Suturing at the beginning of the hepatoduodenal anastomosis. **D, D'**, Formation of the HD in the posterior wall.

11. Safioleas M, Stamatakis M, Safioleas P, Smyrnis A, Revenas C, Safioleas C. Mirizzi syndrome: an unexpected problem of cholelithiasis—our experience with 27 cases. *Int Semin Surg Oncol*. 2008;5:12.

12. Kamalesh NP, Prakash K, Pramila K, et al. Laparoscopic approach is safe and effective in the management of Mirizzi syndrome. *J Minim Access Surg*. 2015;11:246–250.

13. Beltrán MA. Mirizzi syndrome: history, current knowledge and proposal of a simplified classification. *World J Gastroenterol*. 2012;18:4639–4650.

14. Corlette MB, Bismuth H. Biliobiliary fistula: a trap in the surgery of cholelithiasis. *Arch Surg*. 1975;110:377–383.

15. Piccinni G, Sciusco A, De Luca GM, et al. Minimally invasive treatment of Mirizzi's syndrome: is there a safe way? Report of a case series. *Ann Hepatol*. 2014;13:558–564.

16. Yamashita Y, Kimura T, Matsumoto S. A safe laparoscopic cholecystectomy depends upon the establishment of a critical view of safety. *Surg Today*. 2010;40:507–513.

17. Tuveri M, Tuveri A. Body-first laparoscopic cholecystectomy: a three-trocar technique for difficult gallbladders. *J Laparoendosc Adv Surg Tech A*. 2009;19:415–418.

18. Philips JAE, Lawes DA, Cook AJ, Arulampalam TH, Zaborsky

A, Menzies D. The use of laparoscopic subtotal cholecystectomy for complicated cholelithiasis. *Surg Endosc*. 2008;22:1697–1700.

19. Stefanini P, Carboni M, Patrassi N, Basoli A, de Bernardinis G, Negro P. Roux-en-Y hepaticojejunostomy: a reappraisal of its indications and results. *Ann Surg*. 1975;181:213–219.

20. Santore MT, Deans KJ, Behar BJ, Blinman TA, Adzick NS, Flake AW. Laparoscopic hepaticoduodenostomy versus open hepaticoduodenostomy for reconstruction after resection of choledochal cyst. *J Laparoendosc Adv Surg Tech A*. 2011;21:375–378.

21. Patil V, Kanetkar V, Talpallikar MC. Hepaticoduodenostomy for biliary reconstruction after surgical resection of choledochal cyst: a 25-year experience. *Indian J Surg*. 2015;77:240–244.

22. Todani T, Watanabe Y, Urushihara N, Noda T, Morotomi Y. Biliary complications after excisional procedure for choledochal cyst. *J Pediatr Surg*. 1995;30:478–481.

23. Todani T, Watanabe Y, Mizuguchi T, Fujii T, Toki A. Hepaticoduodenostomy at the hepatic hilum after excision of choledochal cyst. *Am J Surg*. 1981;142:584–587.

24. Mayo WJ. Some remarks on cases involving operative loss of continuity of the common bile-duct, with the report of a case of anastomosis between the hepatic duct and duodenum. *Ann Surg*. 1905;4:90–96

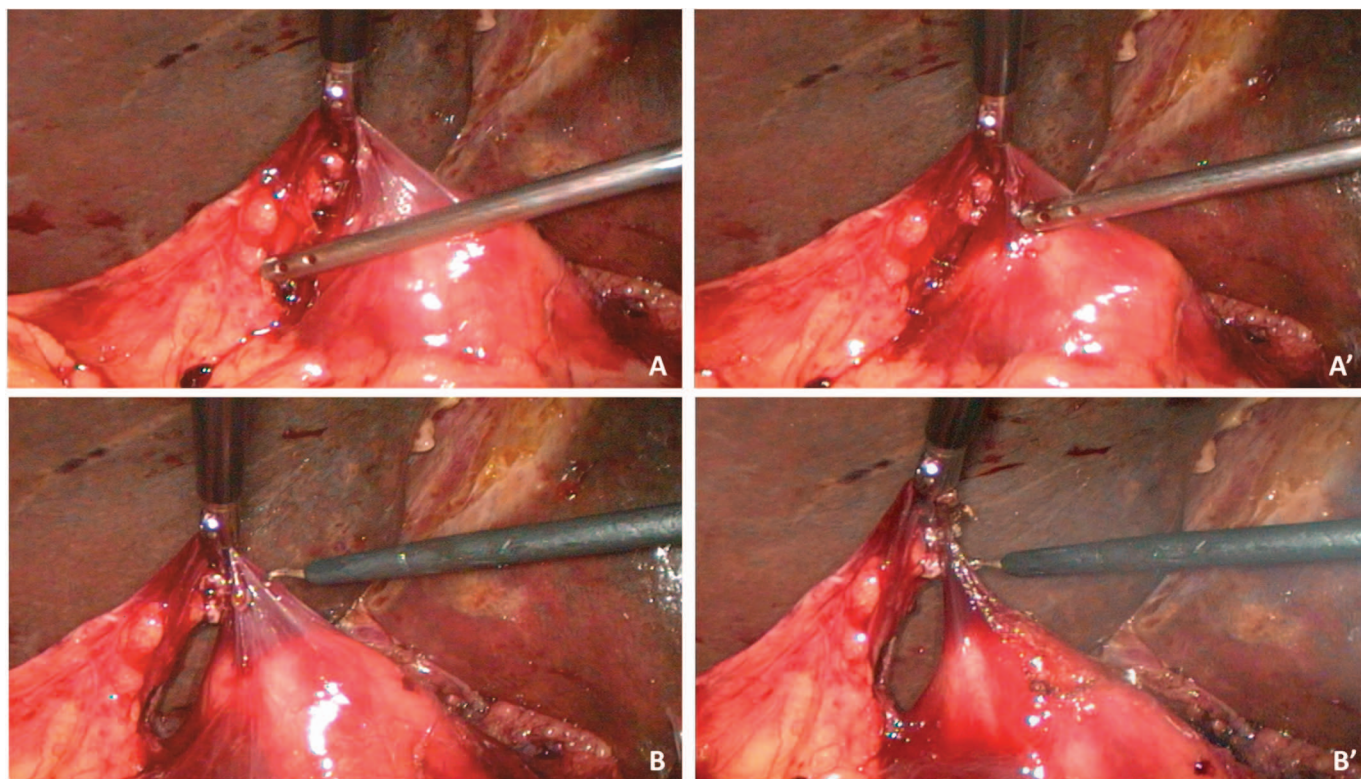


Figure 11. Duodenum release by the Kocher maneuver. **A, A'**, Repair; **B, B'**, release.

25. Rose JB, Bilderback P, Raphaeli T, et al. Use the duodenum, it's right there: a retrospective cohort study comparing biliary reconstruction using either the jejunum or the duodenum. *JAMA Surg.* 2013;148:860–865.

26. Yeung PHY, Chung KKY, Wong, et al. Biliary-enteric reconstruction with hepaticoduodenostomy following laparoscopic excision of choledochal cyst is associated with better postoperative outcomes: a single-centre experience. *Pediatr Surg Int.* 2015;31:149–153.

27. Liem NT, Dung LA, Son TN. Laparoscopic complete cyst excision and hepaticoduodenostomy for choledochal cyst: early results in 74 cases. *J Laparoendosc Adv Surg Tech.* 2009;19:87–90.

28. Firme WA, Carvalho GL, Lima DL, et al. Low-friction mini-laparoscopy outperforms regular 5-mm and 3-mm instruments for precise tasks. *JSLS.* 2015;9:19. pii: e2015.00067. doi: 10.4293/JSLS.2015.00067.

29. Araujo SEA, Mendes CRS, Carvalho GL, Lyra M. Surgeons' perceptions of transanal endoscopic microsurgery using mini-laparoscopic instruments in a simulator: the thinner the better. *Surg Endosc.* 2015;29:2331–2338.

30. Carvalho GL, Cavazzola LT, Rao P. Minilaparoscopic surgery—not just a pretty face! What can be found beyond the esthetics reasons? *J Laparoendosc Adv Surg Tech A.* 2013;23:710–713.