

Laparoscopic Removal of Auto-amputated Adnexa in Newborns and Infants

Mirko Bertozzi, MD, Antonino Appignani, MD, PhD

Struttura Complessa di Clinica Chirurgica Pediatrica—Università degli Studi di Perugia, Ospedale S. Maria della Misericordia, 06100 S. Andrea delle Fratte, Perugia, Italy (both authors).

ABSTRACT

Introduction: Adnexal auto-amputation is a rare complication of fetal ovarian torsion. We present a case of adnexal auto-amputation and its laparoscopic treatment in a newborn. In this article, to discuss different techniques, we also reviewed newborn and infant cases of adnexal auto-amputation reported in the literature and treated laparoscopically.

Case Description/Technique Description: A 2-week-old newborn with a preoperative ultrasonography suggesting a possible auto-amputation of the left ovary underwent laparoscopic 2-trocar removal of a hemorrhagic cyst measuring 4.5 cm in diameter. Laparoscopy was performed, without any major intraoperative complications such as bleeding, rupture, or leakage.

All structures were correctly identified. After transabdominal suction, the hemorrhagic cyst was delivered from the umbilical 10-mm port and removed. The presence of a blind adnexal stump was evidence of auto-amputation. The contralateral ovary was verified. The postoperative course was uneventful, and the patient was discharged on postoperative day 2.

Discussion: Although laparoscopic removal of auto-amputated adnexa can be successfully accomplished in newborns and infants, 50% of auto-amputated adnexa are still treated by laparotomy. Our review revealed the necessity of ≥ 2 ports for identification and removal of the adnexa by laparoscopic-assisted technique, while 3 trocars proved useful in the presence of tenacious adhesions.

Key Words: Auto-amputated adnexa, Infants, Laparoscopy, Newborns.

Citation Bertozzi M, Appignani A. Laparoscopic removal of auto-amputated adnexa in newborns and infants. CRSLS e2014.00093. DOI: 10.4293/CRSLS.2014.00093.

Copyright © 2015 by SLS, Society of Laparoendoscopic Surgeons. This is an open-access article distributed under the terms of the Creative Commons Attribution-Noncommercial-ShareAlike 3.0 Unported license, which permits unrestricted noncommercial use, distribution, and reproduction in any medium, provided the original author and source are credited.

Address correspondence to: Mirko Bertozzi, S.C. di Clinica Chirurgica Pediatrica, Università degli Studi di Perugia, Ospedale S. Maria della Misericordia, Loc. S. Andrea delle Fratte, 06100 Perugia, Italy. Telephone: +39-075-5783376, Mobile: +39-339-3196807, Fax: +39-075-5783376, E-mail: mirkobertozzi@hotmail.com

INTRODUCTION

Auto-amputation of the ovary has been reported in both children and adults, and it is thought to result from the torsion of a normal or cystic ovary, with subsequent infarction, necrosis, and detachment.^{1–3} The auto-amputated structure may adhere to another surface or become a free-floating, possibly calcified intraperitoneal item. Auto-amputated adnexa can probably be hypothesized in cases presenting with freely mobile or variable location abdominal masses at ultrasonographic scanning (USS). The definitive diagnosis of this rare complication can be made only after surgical exploration. Although in the last 15 years, minimally invasive surgery has become wide-

spread also in newborns, laparoscopic treatment of auto-amputated adnexa is rarely reported in literature.

Case Description

A 36-week-old female fetus presented a left lower abdominal cystic mass measuring 4.0×3.2 cm on antenatal USS. The baby was born at 40 weeks of gestation age with an uneventful vaginal delivery and a birth weight of 3650 g. Physical examination results were normal, with no palpable abdominal mass. Hematologic and biochemical investigations were normal.

Postdelivery USS revealed a cystic mass measuring 4.9×3.2 cm in the left pelvis with a significant echogenicity

indicating hemorrhagic content and no evidence of vascular perfusion at color-flow Doppler scanning. After 15 days, another USS showed that the dimensions of the mass remained unvaried. Because of this finding, our radiologists hypothesized an auto-amputation or prenatal adnexal torsion; therefore, surgery was planned and the newborn underwent elective laparoscopy. The procedure was performed under general anesthesia. Physical examination performed before surgery on the patient under anesthesia revealed a round palpable mass in the left lower abdomen.

A 10-mm port with pneumatic anchorage was inserted

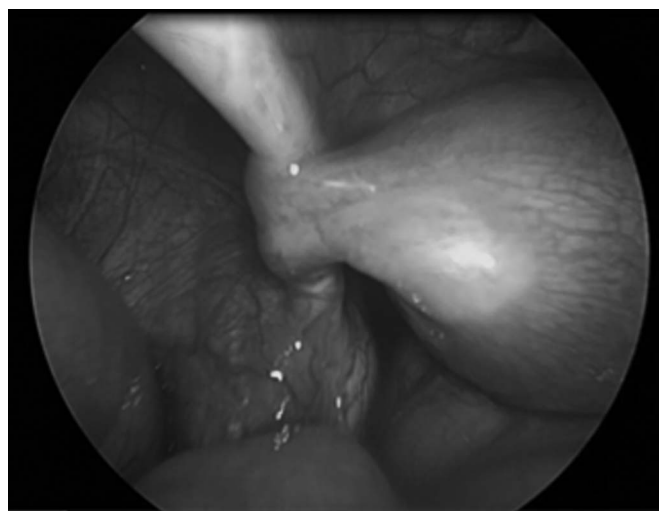


Figure 1. Inspection of the genitalia showing the absence of the left ovary and a blind short stump of the left fallopian tube.

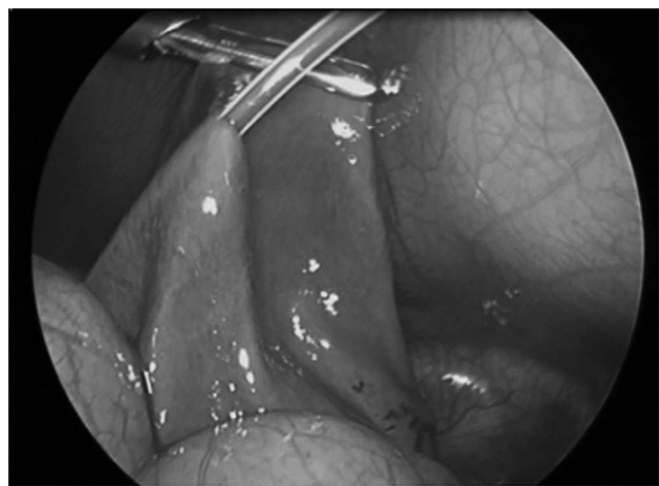

Figure 2. The annex was partially drained by an intravenous 14-gauge catheter inserted through the abdominal wall under direct laparoscopic vision.

through the umbilical incision using the Hasson technique. The abdomen was insufflated to a pressure of 6 mm Hg. A brown smooth cystic lesion measuring approximately 4.5 cm was found in the left iliac fossa.

A second operative 3-mm port was placed in the left flank. Inspection of genitalia revealed absence of the left ovary and a left fallopian tube ending in a blind short stump (**Figure 1**). The right ovary was explored and found normal.

The cyst was then mobilized with an atraumatic grasper. An intravenous 14-gauge catheter was inserted through the abdominal wall just over the cyst and under direct laparoscopic vision through the wall of the cyst. Aspiration of the cyst's content was performed, avoiding spillage, by suction of 30 mL of hemorrhagic fluid until the cyst was partially drained (**Figure 2**). The needle was withdrawn and the cyst was moved with the grasp until it was situated just under the umbilical port, and then it was completely delivered through the umbilical incision (**Figure 3**). The exteriorized cyst appeared to have a fine and loose pedicle ending in the suspensory ligament of the ovary; this was resected extracorporeally by bipolar cauterization. After the complete excision of the cyst, the umbilical incision was closed by skin and fascia sutures and the left incision was repaired by application of sterile strips.

Histological examination showed extensive hemorrhagic necrotic autolytic tissue with dystrophic calcification, containing ovarian tissue and congestion of the ovarian vessels with thrombosis. The postoperative course was uneventful, and the patient was discharged on postoperative day 2.

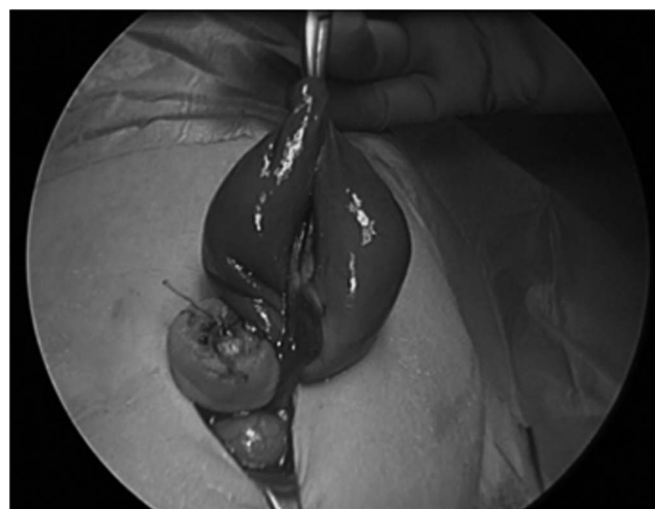

Figure 3. The annex was completely delivered through the 10-mm umbilical incision.

DISCUSSION

Fetal ovaries are subject to the development of cysts because of the surrounding hormonal environment. Most of these are small simple cysts. Infants with simple cysts <4 cm in diameter should be initially approached conservatively with a postnatal USS follow-up, as most of these cysts will resolve spontaneously. Larger cysts may require surgical intervention, especially if the lesions convert from simple to complex on ultrasonographic imaging, suggesting hemorrhage or torsion, or if the neonate is symptomatic.⁴ Although there have been reports of some rare cases of benign cystic teratomas, ovarian cysts in infants are generally benign.^{5,6}

Pre- or postnatal ovarian cyst complications are rather frequent and include intracystic bleeding and torsion of the cyst or of its corresponding annex. The incidence of fetal ovarian torsion as a complication of ovarian cysts was reported to be as high as 50% to 78%.^{7,8}

Torsion of cysts can cause complications such as intestinal obstruction or perforation or rupture of the cyst, whereas consequences of adnexal torsion may be catastrophic.⁹

Although rarely seen, an auto-amputation could be the final sequel of ischemia and infarction of adnexa torsion. The auto-amputated adnexa can cause complications such as acute abdomen¹⁰ and amputated-tumor reimplantation in the omentum.¹¹ Considering these possibilities, some investigators suggest that early surgical removal of auto-amputated adnexa is preferable to a wait-and-see approach.¹²

Although an auto-amputated annex is a rare but well known result of adnexal torsion, preoperative diagnosis remains a challenge. Some investigators consider a freely mobile mass, also known as a “wandering tumor” or “free-floating” abdominal cyst, as a sign of an auto-amputated annex; however, it is sometimes difficult to determine this finding in a neonate while a “side change” as reported by Kuwata et al¹³ may be quite easy to notice. We think that a cystic mass with a significantly echoic content indicating a hemorrhagic cyst and no evidence of vascular perfusion at color-flow Doppler scanning associated to the signs described herein strongly suggests the diagnosis of auto-amputated annex.

Historically, in the case of surgical intervention, auto-amputated adnexa have been treated by laparotomy; however, modern laparoscopic equipment provides a much less invasive alternative. The use of minimally invasive surgery in newborns is becoming well accepted, and, in the last 15

years, the increasing experience has led to an increased spectrum of these kinds of procedures. Nevertheless, since the first reported case of auto-amputated annex laparoscopically removed in an infant,¹⁴ about 50% of the reported cases are still treated by laparotomy.¹⁵

To date, in English medical literature, only 7 papers report a laparoscopic treatment of auto-amputated adnexa in newborns and infants with a total of 12 cases removed.^{13,14,16–20}

Data analyzed included the following information: laparoscopic procedure, prenatal diagnosis, age at the moment of the intervention, preoperative diagnosis, reasons for surgical intervention, annex involved (**Table 1**).

To analyze different laparoscopic techniques for all cases, we also collected a description of carboperitoneum pressure, number of trocars used, umbilical port size, camera size, place and size of operative ports, exteriorization cyst method, and the cyst's attachments. Our review identified another 12 cases of auto-amputated adnexa treated laparoscopically in infants and newborns. Six investigators published case reports, 1 investigator reported 2 cases and 1 investigator reported a case series of 5 patients. Five of 13 patients were treated as newborns. The data regarding the 5 additional patients presented by Tseng et al¹⁷ were summarized in aggregates (age ranging from 9 days to 7.5 months). All patients except 1 (12 of 13) had a prenatal diagnosis of fetal cyst identified via ultrasonography.

Surgical intervention was planned for increasing size of cyst, no signs of reduction, or complex cysts, except in 1 case where intervention was performed for suspicion of enteric duplication.

Only 4 patients had a mobile mass present in the peritoneal cavity, 2 of these masses were free-floating cysts and the other 2 were side-changing cysts.

Excluding the cumulative data, the left ovary was involved in most cases (7 of 8).

Laparoscopic intervention was performed using a carboperitoneum with a pressure from 8 to 10 mm Hg in 3 cases and from 6 to 10 mm Hg in 5 cases. A carboperitoneum of 8 mm Hg was recorded in 2 cases, in 1 case it was of 6 mm Hg, and in 2 cases it was not reported.

The number of trocars used were, respectively, 1 in 1 case, 2 in 4 cases, and 3 in 3 cases. Umbilical port size was reported in 9 cases ranging from 5 to 12 mm while camera size, if described, was 5 mm in all cases.

Table 1.
Review of Literature About Laparoscopic Treatment of Auto-amputated Adnexa in Newborns and Infants

Author (Year)	Patients, n	Prenatal US Diagnosis	Age at Intervention	Preoperative Diagnosis	Reasons for Surgical Intervention	Annex Involved	Carbopertoneum, mm Hg	Trocars, n	Umbilical Port Size, mm	Camera Size, mm	Operative Ports Size (mm) and Place	Exteriorization Cyst's Method	Cyst's Attachments	Postoperative Hospital Stay, day(s)
Jawad et al (1998)	1	3.4 × 3.1 cm cystic mass	5 months	US: 4.2 × 3.7 cm pelvic cystic mass with echogenic findings	Increased size	Left tube/ovary	8	2	10	5	1 (5-mm port) right iliac fossa	Opened and suctioned through the umbilical port	—	2
Decker et al (1999)	1	Pelvic cyst	6 weeks	US: 3.0 × 4.0 complex right ovarian cyst with echogenic findings	Increased size and complex cysts	Right tube/ovary	8–10	3	—	5	2 (5-mm ports) left and right upper quadrants	Delivered entirely by enlarging the umbilical port	Cyst hilum attached to the omentum	1
Tseng et al (2002)	5	Cystic masses, range 3.7 to 6.5 cm	Range 9 d to 7.5 months	US: Complex cystic masses, range 3.9 to 7.6 cm	Increased size and complex cysts	—	6–10	2	5	—	1 (3-/5-mm port) left midabdomen	Intracorporeally aspirated through the umbilical port	4 cases: tethered by a fine vascular pedicle from the suspensory ligament of the ovary	1
Visnjic et al (2008)	1	4 cm diameter cyst left lower abdomen	4 weeks	US: 4.5 cm cystic mass with echogenic findings on right side of the abdomen	No signs of reduction and complex cyst	Left tube/ovary	8	2	12	—	1 (5-mm port) left lower abdominal quadrant	Percutaneously aspirated by needle	Loose adhesions	—
Zampieri et al (2009)	2	3.5 × 3 cm abdominal cyst, 3.5 × 4.5 pelvic cyst	2 days, 2 days	US: 5.2 × 6 cm free-floating abdominal cyst without blood support and fluid/debris levels, US: 4.5 × 5 cm free-floating abdominal cyst	Increased size and complex cysts	Left tube/ovary, left tube/ovary	8–10	3, 1	5	—	2 (5-mm ports)	Percutaneously aspirated by needle	—	—
Kuwata et al (2011)	1	4.3 × 3.6 cm abdominal cyst with echogenic content	4 days	MRI confirming prenatal US with "side-changing"	Increased size and complex cysts	Left tube/ovary	—	—	—	—	—	—	—	—

Table 1 continued on next page

Table 1. (Continued)
Review of Literature About Laparoscopic Treatment of Auto-amputated Adnexa in Newborns and Infants

Author (Year)	Patients, <i>n</i>	Prenatal US Diagnosis	Age at Intervention	Preoperative Diagnosis	Reasons for Surgical Intervention	Annex Involved	Carbopertitoneum, mm Hg	Trocars, <i>n</i>	Umbilical Port Size, mm	Camera Size, mm	Operative Ports Size (mm) and Place	Exteriorization Cyst's Method	Cyst's Attachments	Postoperative Hospital Stay, day(s)
Castellani et al (2013)	1	—	2.5 months	US: abdominal complex cyst	Suspected enteric duplication	Left tube/ ovary	—	3	—	5	2 (3-mm ports) left and right midabdomen	—	2 pedicles: one ending at the antimesenteric border of the midsignoid colon and the other in the greater omentum	5
Present case	1	4.0 × 3.2 cm left lower abdominal cyst	15 days	US: 4.9 × 3.2 cm cystic mass with echogenic findings without blood support on the left pelvis	Increased size and complex cysts	Left tube/ ovary	5	2	10	5	1 (3-mm port) left midabdomen	Percutaneously aspirated by needle	Fine pedicle ending in the suspensory ligament of the ovary	2

Abbreviations: MRI, magnetic resonance imaging; US, ultrasonography; —, not reported.
Details about description of prenatal ultrasonographic findings, age at the intervention, postnatal ultrasonographic or magnetic resonance imaging description, reasons for surgical intervention, and annex involved are reported.
The table shows also technical details of different laparoscopic procedures for auto-amputated adnexa in newborns and infants reported in the literature, details of the removed annex, and the postoperative hospital stay.

Operative ports size and placement, cyst exteriorization method, and cyst attachments are described in **Table 1**. Postoperative hospitalization ranged from 1 to 5 days.

Carboperitoneum was established with a pressure ranging from 6 to 10 mm Hg. We think that because carboperitoneum pressure and its duration can cause possible complications in newborns²¹ that low pressures are preferable. In our case, we adopted a trocar with pneumatic anchorage. Thanks to this device, the assistant surgeon could perform a slight abdominal wall traction allowing us to have a good working space at low pressure.²²

The number of ports used for the removal varies from 1 to 3 according to different investigators. For auto-amputated adnexa with loose adhesions or fine pedicles, the use of 2 trocars appears to be safe, as does the 3-trocars technique. In the case of more tenacious adhesions, the use of 3 trocars is necessary. The use of only 1 trocar with a 5-mm size camera described by Zampieri et al¹⁹ in one of their cases seems to be only diagnostic because the entire drainage and removal of the auto-amputated annex was accomplished through the umbilical incision without need of laparoscopy. The operative ports size ranged from 3 to 5 mm. Camera size was 5 mm for all investigators when reported, but only 5 investigators report the size of umbilical port. This point may be discussed because the umbilical port ranges from 5 to 12 mm. Only Decker et al¹⁶ describes the delivery of the entire auto-amputated annex without its drainage by enlarging the umbilical port incision. The remaining investigators adopt intra-abdominal drainage of the annex then its delivery through the umbilical incision. Adnexa delivery through a 5-mm port after intracorporeal suction is reported by 2 investigators,^{17,19} but it is reasonable to think that this maneuver is not simple to perform and can become dangerous. The increasing manipulation during adnexa delivery through a 5-mm incision may in fact lead to a possible risk of perforation and peritoneal spillage. In our experience, a 10-mm umbilical incision is a good choice for laparoscopic-assisted excision of abdominal cystic masses,^{23,24} and, in the case described earlier, it seems to be effective for annex delivery after its intracorporeal suction. When the auto-amputated annex is delivered from the umbilical incision, loose adhesions can be easily resected extracorporeally.

Our choice to use a 10-mm umbilical and a 3-mm operative trocar appeared safe and effective with minimal abdominal traumatism and postoperative scars. The 10-mm umbilical incision resulted a good choice to exteriorize

easily the drained cyst without a possible perforation and/or spillage. Regarding cosmetic results, the 10-mm incision was hidden by the umbilical scar while the 3-mm incision left a nearly invisible scar.

CONCLUSIONS

Although laparoscopic removal of auto-amputated adnexa can be successfully accomplished in newborns and infants, 50% of auto-amputated adnexa are still treated by laparotomy. During neonatal laparoscopic procedures, low pressures of carboperitoneum are preferable to avoid related complications. There are many differences among investigators regarding trocar size and umbilical port size. This review revealed the necessity of ≥ 2 ports for identification and removal of the adnexa by laparoscopic-assisted technique, while 3 trocars proved useful in the presence of tenacious adhesions between the adnexa and other tissues.

Although the articles published on this subject are not numerous, the investigators apply similar techniques but with differences in the number and size of trocars and in the auto-amputated adnexa delivery technique.

References:

1. Nixon GW, Condon VR. Amputated ovary: a cause of migratory abdominal calcification. *AJR Am J Roentgenol*. 1977;128(6):1053–1055.
2. Kennedy LA, Pinckney LE, Currarino G, Votteler TP. Amputated calcified ovaries in children. *Radiology*. 1981;141(1):83–86.
3. Keshtgar AS, Turnock RR. Wandering calcified ovary in children. *Pediatr Surg Int*. 1997;12(2–3):215–216.
4. Luzzatto C, Midrio P, Toffolutti T, Suma V. Neonatal ovarian cysts: management and follow-up. *Pediatr Surg Int*. 2000;16(1–2):56–59.
5. Ikeda K, Suita S, Nakano H. Management of ovarian cyst detected antenatally. *J Pediatr Surg*. 1988;23(5):432–435.
6. Shalev E, Mann S, Romano S, Rahav D. Laparoscopic detorsion of adnexa in childhood: a case report. *J Pediatr Surg*. 1991;26(10):1193–1194.
7. Jawad AJ, Zaghmout O, Al-Muzrakchi AD, al-Hammadi T. Laparoscopic removal of an autoamputated ovarian cyst in an infant. *Pediatr Surg Int*. 1998;13(2–3):195–196.
8. Bagolan P, Giorlandino C, Nahom A, et al. The management of fetal ovarian cysts. *J Pediatr Surg*. 2002;37(1):25–30.
9. Fitzhugh VA, Shaikh JR, Heller DS. Adnexal torsion leading to death of an infant. *J Pediatr Adolesc Gynecol*. 2008;21(5):295–297.

10. Uygun I, Aydogdu B, Okur MH, Otcu S. The first report of an intraperitoneal free-floating mass (an autoamputated ovary) causing an acute abdomen in a child. *Case Rep Surg*. 2012;2012: 615734. doi: 10.1155/2012/615734.
11. Ushakov FB, Meirow D, Prus D, Libson E, BenShushan A, Rojansky N. Parasitic ovarian dermoid tumor of the omentum: a review of the literature and report of two new cases. *Eur J Obstet Gynecol Reprod Biol*. 1998;81(1):77–82.
12. Koike Y, Inoue M, Uchida K, et al. Ovarian autoamputation in a neonate: a case report with literature review. *Pediatr Surg Int*. 2009;25(7):655–658.
13. Kuwata T, Matsubara S, Maeda K. Autoamputation of fetal/neonatal ovarian tumor suspected by a “side change” of the tumor. *J Reprod Med*. 2011;56(1–2):91–92.
14. Jawad AJ, Zaghmout O, al-Muzrakchi AD, al-Hammadi T. Laparoscopic removal of an autoamputated ovarian cyst in an infant. *Pediatr Surg Int*. 1998;13(2–3):195–196.
15. Focseneanu MA, Omurtag K, Ratts VS, Merritt DF. The auto-amputated adnexa: a review of findings in a pediatric population. *J Pediatr Adolesc Gynecol*. 2013;26(6):305–313.
16. Decker PA, Chammas J, Sato TT. Laparoscopic diagnosis and management of ovarian torsion in the newborn. *JSL*. 1999;3(2): 141–143.
17. Tseng D, Curran TJ, Silen ML. Minimally invasive management of the prenatally torsed ovarian cyst. *J Pediatr Surg*. 2002; 37(10):1467–1469.
18. Visnjic S, Domljan M, Zupancic B. Two-port laparoscopic management of an autoamputated ovarian cyst in a newborn. *J Minim Invasive Gynecol*. 2008;15(3):366–369.
19. Zampieri N, Scirè G, Zambon C, Ottolenghi A, Camoglio FS. Unusual presentation of antenatal ovarian torsion: free-floating abdominal cysts. Our experience and surgical management. *J Laparoendosc Adv Surg Tech A*. 2009;19 Suppl 1:S149–S152.
20. Castellani C, Petnehazy T, Gürtl-Lackner B, Saxena AK. A rare cause for a neonatal cystic abdominal mass. *J Minim Invasive Gynecol*. 2013;20(5):714–716.
21. Olsen M, Avery N, Khurana S, Laing R. Pneumoperitoneum for neonatal laparoscopy: how safe is it? *Paediatr Anaesth*. 2013;23(5):457–459.
22. Bertozzi M, Prestipino M, Nardi N, Appignani A. Preliminary experience with a new approach for infantile hypertrophic pyloric stenosis: the single-port, laparoscopic-assisted pyloromyotomy. *Surg Endosc*. 2011;25(6):2039–2043.
23. Bertozzi M, Nardi N, Prestipino M, Magrini E, Appignani A. Minimally invasive removal of urachal remnants in childhood. *Pediatr Med Chir*. 2009;31(6):265–268.
24. Bertozzi M, Appignani A. Laparoscopic diagnosis and excision of a giant sigmoid cystic duplication. *CRSLS*. 2014; e2014.00238. DOI: 10.4293/CRSLS.2014.00238.