

Supine Robotic-Assisted Retroperitoneal Lymph Node Dissection for Testicular Cancer

Michael G. Santomauro, MD, Sean P. Stroup, MD, Audry H. L'Esperance, BS,
James H. Masterson, MD, Ithaar H. Derweesh, MD, Brian K. Auge, MD, Donald S. Crain, MD,
and James O. L'Esperance, M.D

Department of Urology, Naval Medical Center San Diego, San Diego, CA, USA (Drs Santomauro, Stroup, Masterson, Auge, Crain, J. L'Esperance, and Ms A. L'Esperance).

Division of Urology, University of California, San Diego, CA, USA (Drs Stroup and Derweesh).

ABSTRACT

Background and Objectives: Robotic-assisted laparoscopic retroperitoneal lymph node dissection (RPLND) using a lower abdominal approach for testicular cancer is an advanced and relatively new surgical technique. Herein we describe technical modifications, review benefits, and report our initial series.

Methods: A retrospective review of 16 patients from Jan 1, 2010 to Dec 31, 2012 who underwent robotic RPLND for nonseminomatous germ cell tumors was performed. Patients were positioned in 15° of Trendelenburg and tilted 15° to the right. An infraumbilical midline camera port, 3 robotic ports, and 2 assistant ports were placed in a lower abdominal configuration. Patient demographic and perioperative outcomes were assessed.

Results: Twelve patients underwent staging, prospective nerve-sparing RPLNDs, and 4 underwent postchemotherapy RPLNDs. Mean age was 26.4 years with a mean body mass index of 27.4 kg/m². The cohort had a mean operative time of 357 minutes, mean estimated blood loss of 205 mL, mean hospital stay of 3.6 days, and mean postoperative morphine equivalent use of 47.1 mg. There were no conversions to open RPLND in this cohort. An average of 26.2 lymph nodes were sampled.

Conclusions: Inferior approach for robotic RPLND enables a thorough dissection of the retroperitoneum, without repositioning, to meet oncologic goals. Further study to evaluate long-term outcomes is warranted.

Key Words: Retroperitoneal lymph node dissection, Robotic surgery, Surgical approaches, Technical modifications, Testicular cancer.

Citation Santomauro MG, Stroup SP, L'Esperance AH, Masterson JH, Derweesh IH, Auge BK, Crain DS, L'Esperance JO. Supine robotic-assisted retroperitoneal lymph node dissection for testicular cancer. CRSLS e2014.00326. DOI: 10.4293/CRSLS.2014.00326.

Copyright © 2014 SLS This is an open-access article distributed under the terms of the Creative Commons Attribution-Noncommercial-ShareAlike 3.0 Unported license, which permits unrestricted noncommercial use, distribution, and reproduction in any medium, provided the original author and source are credited.

Conflict of Interest Disclosures: Drs Stroup, Auge, and J. L'Esperance are consultants for Intuitive Surgical. Dr Derweesh has participated in a clinical trial funded by and is a consult for GlaxoSmithKline. All other authors have reported that they have no relationships relevant to the contents of this article to disclose.

Disclaimer: The views expressed in this article are those of the authors and do not reflect the official policy or position of the Department of the Navy, Department of Defense, or the United States Government.

Address correspondence to: James O. L'Esperance, MD, CDR, MC, USN, Urology Residency Program Director, Director of Robotic Surgery, Department of Urology Naval Medical Center San Diego, 34800 Bob Wilson Dr, San Diego, CA 92134. Telephone: (619) 532-7202, Fax: (619) 532-7234, E-mail: james.lesperance@med.navy.mil

INTRODUCTION

Testicular cancer is the most common malignancy in men between the ages of 15 and 35 years.¹ In patients diagnosed with stage I nonseminomatous germ cell tumors, treatment options include close surveillance, chemotherapy, and retroperitoneal lymph node dissection (RPLND).^{2,3} Accurate clinical staging with axial imaging is crucial in

the management of testicular cancer patients after radical orchiectomy. There has been increasing concern that operative and postoperative morbidity may render the primary (staging) RPLND obsolete, especially with such effective chemotherapeutic options. The fact remains, however, that chemotherapy is not without potential drawbacks and long-term data on 1 or 2 cycles in the stage

I setting do not exist. Additively, surveillance can be quite limiting for some patients and career-altering at times based on the frequency of follow-up and intensity of the imaging schedule, making compliance an issue. If the morbidity of RPLND can be minimized, it may represent a much more attractive option for patients who fall into this category. One scenario that is a clear indication for RPLND occurs in the postchemotherapeutic population with measurable residual disease on imaging along with negative serum markers. Based on the complexity resulting from chemotherapy-related scarring, an open approach is clearly warranted in many of these patients, but a minimally invasive approach is still feasible in select postchemotherapy patients.

RPLND for stage I nonseminomatous germ cell tumors has been shown to be the most sensitive and specific method for testicular cancer staging and allows for immediate stratification for further treatment options.⁴ Classically, open RPLND has been the method of choice at most centers.⁵ However, open RPLND is associated with substantial morbidity. To address the morbidity concerns, laparoscopic or robotic RPLND have been developed as therapeutic options. Minimally invasive approaches seek to uphold oncological principles established from the open experience and enable bilateral dissections to improve outcomes, while decreasing morbidity.^{2,6}

Although these advantages have made robotic RPLND an increasingly popular treatment option among surgeons and patients, questions remain about the most ideal patient positioning, surgical approach, resection template, and adequacy of the node dissection. With a number of experienced laparoscopic and robotic surgeons and a significant case volume, we have adopted robotic RPLND as a preferred approach at our institution. Our initial approach employed high abdominal trocar placement and upward bowel retraction. While this approach afforded excellent retroperitoneal access and highlighted the advantages of robotic instrumentation, it proved to be technically challenging for the bedside assistant and console surgeon alike. This was most notable during renal hilar dissection. These earlier cases elucidated the subtleties of bowel preparation. Namely, full bowel preparation resulted in bowel edema and increased technical difficulty. We began to focus on decreasing bowel edema and gas rather than true bowel preparation. This has proven helpful, with all approaches, in decreasing the difficulty of dealing with bowel manipulation during dissection.

The decision to adopt a lower abdominal approach was based mostly on the difficulty in dealing with bowel re-

traction when using the high abdominal approach near the renal hilum. We have been increasingly impressed with the consistency and reproducibility of retroperitoneal access while employing this lower abdominal approach. Herein, we report our initial experience with robotic RPLND and describe our low abdominal surgical approach.

MATERIALS AND METHODS

We conducted a retrospective review of 16 patients undergoing a planned robotic RPLND for testicular cancer, using our Institutional Review Board–approved urologic surgery database. All patients underwent a complete preoperative staging at our institution after their radical orchiectomy that included a chest-abdomen-pelvis computed tomography scan, standard labs, and appropriate tumor markers. The decision to proceed with a robotic RPLND was based on the patient's informed consent and discussions held at our interdisciplinary tumor board, where all options, including RPLND, were discussed for each patient.

We offered robotic RPLND to patients who were eligible for primary (staging) RPLND as well as to patients with postchemotherapy residual disease that was deemed robotically resectable based on imaging. All patients, including postchemotherapy patients, had negative tumor markers at the time of surgery. Patients selected for this approach had no prior history of major abdominal surgery. Those with large residual masses that were of concern for aortic/inferior vena cava (IVC) involvement were either excluded from a minimally invasive approach or counseled regarding the high conversion rates. Those with elevated tumor markers were also excluded.

Patient demographic and perioperative variables including operative time, blood loss, length of stay, conversion to open surgery, narcotic usage, and pathologic outcomes were assessed (**Table 1**). We carefully analyzed the cohort for complications using the modified Clavien classification system for surgical patients.^{7,8}

Surgical Technique

Preoperatively, patients underwent an oral mechanical bowel preparation consisting of 300 mL of magnesium citrate and a clear liquid diet on the day prior to surgery. Additionally, 80 mg of simethicone was given 3 times per day for 1 week preoperatively until the morning of surgery to diminish bowel gas burden.

In the operating room, general anesthesia was established and an orogastric tube was placed. The patient was placed

Table 1.
Patient Data

Patients (<i>n</i> = 16)	
Mean age	26.4 yrs (22–39)
BMI	27.4 kg/m ² (21.6–33.4)
Mean operative time	357 min (233–716)
Mean EBL	205 mL (25–450)
Mean hospital stay	3.6 days (2–6)
Morphine equivalent use	47.1 mg (0–179)
Mean number of lymph nodes sampled	26.2 (8–41)

Abbreviations: BMI, body mass index; EBL, estimated blood loss.

supine with moderate Trendelenburg (approximately 10°–15°), pressure points were padded, and secured to the table. Additionally, the patient was rotated approximately 15° to the right. Prior to this positioning, the patient was placed in steep Trendelenburg to facilitate mobilization of the small bowel out of the pelvis. Once this was achieved, the patient was taken slowly back down to 15° to keep the bowel from settling back into the pelvis.

Pneumoperitoneum was obtained with a Veress needle. A total of 6 ports were placed across the lower abdomen: a 12-mm midline camera port placed infraumbilically in the midline approximately 3 cm above the pubic symphysis; 3 robotic trocars; and 2 12-mm access ports for the assistant, placed in a gentle U-shaped arc across the lower abdomen (**Figure 1**).

Before docking the robot, we dissected out the spermatic cord remnant using a handheld 10-mm 30° laparoscope, grasping forceps, and an EnSeal (Ethicon Endo-Surgery, Cincinnati, Ohio) electrocautery device. In left-sided cases, this dissection was taken cephalad from the internal ring, up to and underneath the sigmoid colonic reflection for later completion of spermatic cord removal. In right-sided cases, this dissection was carried to above the level of the common iliac artery.

The robot was then docked over the left shoulder at a 15° offset angle. The robot should be kept as far away from the patient as possible to avoid the limitations of the robotic arm movements. This is especially vital during the lower portion of the dissection down near the right common iliac artery (**Figure 2**). We used monopolar scissors in robotic arm #1 (left lower quadrant), ProGrasp (Intuitive Surgical, Sunnyvale, CA) forceps in robotic arm #2 (right lower quadrant), and Prograsp (Intuitive Surgical,

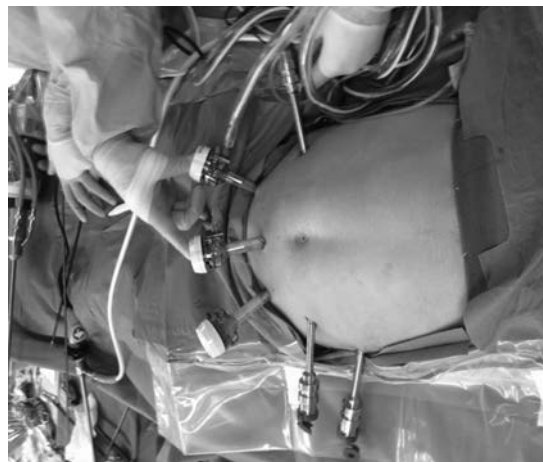

Figure 1. Port placement for robotic RPLND. Notice 2 12-mm assistant ports are placed slightly inferior and on either side of the camera port. The camera port is placed approximately 3 finger widths above the pubic symphysis to avoid bladder injury.

Sunnyvale, CA) forceps in robotic arm #3 (left lateral abdomen just above the umbilicus) Intuitive Surgical, Sunnyvale, CA. Dissection then commenced in an inferior to superior direction. An incision was made in the posterior peritoneum medial to the cecum overlying the right common iliac artery and carried up to the ligament of Treitz, after placing the bowel in the right upper quadrant (**Figure 3**). Gentle dissection then proceeded underneath the mesentery and along the retroperitoneum until the crossing duodenum was encountered. The laterally placed robotic arm #3 (Prograsp) was used to sweep the bowel including the duodenum anteriorly. This was done after the plane between the preperitoneal and retroperitoneal fat was separated. This plane allowed for a working space between the peritoneal structures and the retroperitoneum. Using a Grice needle, 2–0 polyglactin hammock sutures were placed bilaterally through the skin subcostally, lateral to the robotic ports, and then placed through the cut edge of the incised posterior peritoneum and retracted to pull the bowel and peritoneum away from the retroperitoneum in a hammocklike fashion, and secured at the skin level using a hemostat (**Figure 4**). Abdominal contents were then suspended anteriorly via 3 anchoring points: point 1: the third robotic arm anteriorly retracting the duodenum; points 2 and 3: transabdominal sutures placed through both sides of the incised posterior peritoneum and anchored to the skin externally using a hemostat. With these 3 anchoring points in place, dissection was carried out essentially in a tunnel posterior to the bowel. These 2 maneuvers afforded an excellent view of the great vessels and retroperitoneum and provided ade-

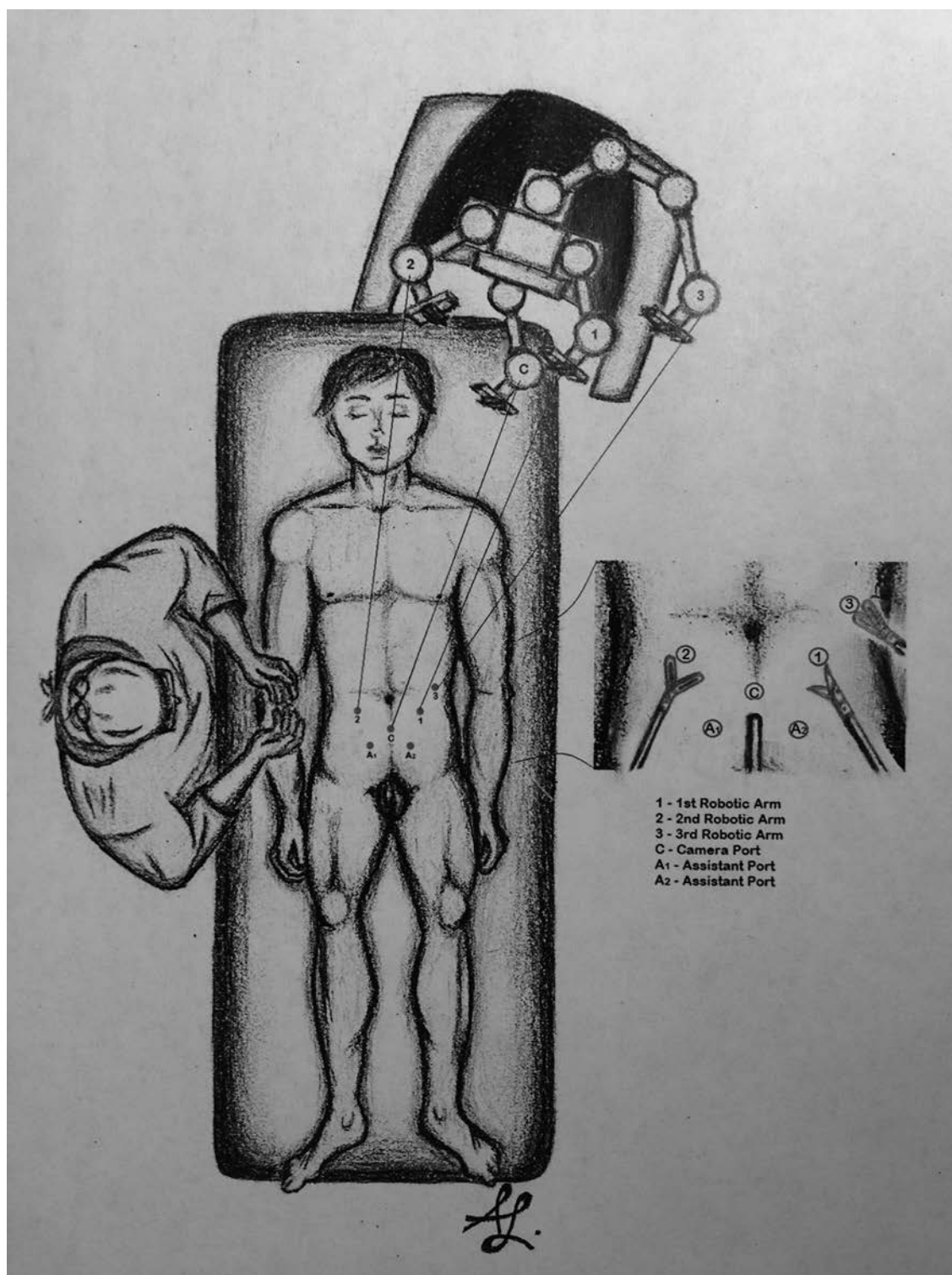


Figure 2. Docking of the da Vinci robot for the robotic RPLND. The surgical robot is brought over the patient's left shoulder at a 15° angle after the patient has been placed in moderate Trendelenburg position (approximately 15°). The robot is left as far away from the patient as possible to avoid reaching robotic arm limits while working on the lower portion of the dissection.

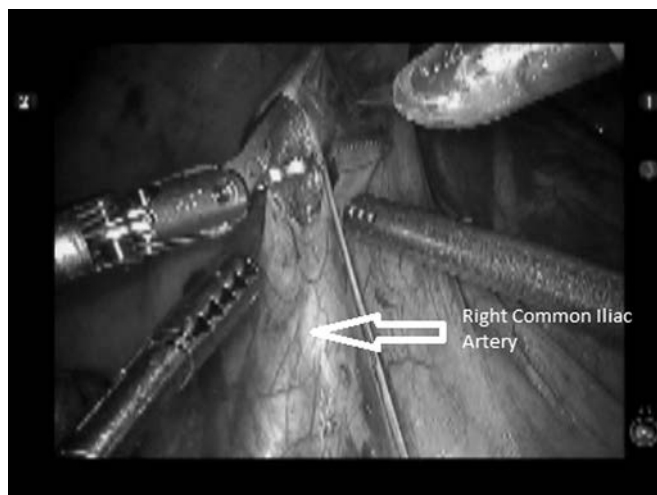


Figure 3. Incision over the right common iliac artery and access to the retroperitoneum.

quate working space throughout the procedure, with minimal retraction of the bowel. Occasionally, additional hammock sutures are used, at the discretion of the operating surgeon, to better retract the peritoneum and keep the bowel from creeping into the working space.

Once the bowel was appropriately retracted and access to the retroperitoneum was secured with the hammock sutures, the lymphadenectomy could be started. On the right side, the lymphatic tissue was split along the midline surface of the IVC and dissected both medially and laterally, in a split-and-roll technique. On the left side of the interaortocaval packet, the renal vein was then traced to the IVC, and the tissue was rolled medially off the IVC to help create the interaortocaval package. Hem-O-Lok polymer clips (Teleflex Medical, Research Triangle Park, North Carolina) secured the superior aspect of the interaortocaval lymph node packet. Once the left renal vein and the renal artery were identified, the dissection proceeded from cephalad to caudad, rolling the lymph node packet off the anterior longitudinal spinal ligament. We took care to preserve most lumbar vessels; however, when necessary, they were divided between Hem-O-Lok clips or with the assistance of the EnSeal electrocautery device.

On the left side, the left ureter was readily identified usually at the medial portion of the suspended retroperitoneum. While dissecting the para-aortic packet, one should mimic the open technique and take care to preserve the inferior mesenteric vein. In addition, when proceeding caudally within the para-aortic packet, the inferior mesenteric artery should be readily identified and preserved. On the right side, the right ureter can be easily

identified in the dependent portion of the swath of tissue contained within the suspended retroperitoneal tissue. The paracaval lymph node packet should be dissected cephalad until the renal hilum is identified. Care should be taken to visualize and preserve, when possible, the lumbar vessels. All lymph node packets can be removed by the assistant using a reusable endocatch bag.

The 3-dimensional visualization and flexibility of the robot facilitated the dissection posterior to the IVC and aorta, with complete removal of nodal tissue over the anterior longitudinal ligament.⁹ Prospectively, sympathetic nerve roots and ganglia are identified and preserved to prevent ejaculatory dysfunction (**Figure 5**). These nerve roots can be prospectively identified over the anterior aspect of the aorta and tracked back to the sympathetic ganglia. Alternatively, they can be tracked from the ganglia, along their course, to the anterior aspect of the aorta and beyond. In either scenario, one cannot perform a split-and-roll technique over the aorta until these nerves have been identified and can be protected.

At the conclusion of the dissection, the abdomen was carefully inspected for bleeding or injury to the surrounding viscera. The posterior peritoneum was returned to its proper anatomical position with removal of the hammock sutures. The posterior peritoneum then can be closed if desired using Hem-O-Lok clips. All trocars were removed under direct vision, and the fascia of the 12-mm assistant ports were closed using a wound closure device. Skin was closed using adhesive glue. No nasogastric tube or Jackson Pratt drains were left at the conclusion of the case.

Postoperative Pathway

Postoperatively, the patients recovered in the surgical ward. Patients are allowed nothing by mouth until postoperative day 1. Pain was controlled using a combination of intravenous acetaminophen and ketorolac, with intravenous narcotics for breakthrough pain. The Foley catheter was removed on postoperative day 1. Patients were allowed clear liquids and advanced to regular diet as tolerated, usually on postoperative day 1. Patients were started on oral narcotics once they were tolerating a regular diet. Early ambulation was encouraged, and patients were usually ready for discharge by postoperative day 3.

RESULTS

Perioperative Details

All 16 patients in our review had nonseminomatous germ cell tumors with negative preoperative tumor markers.

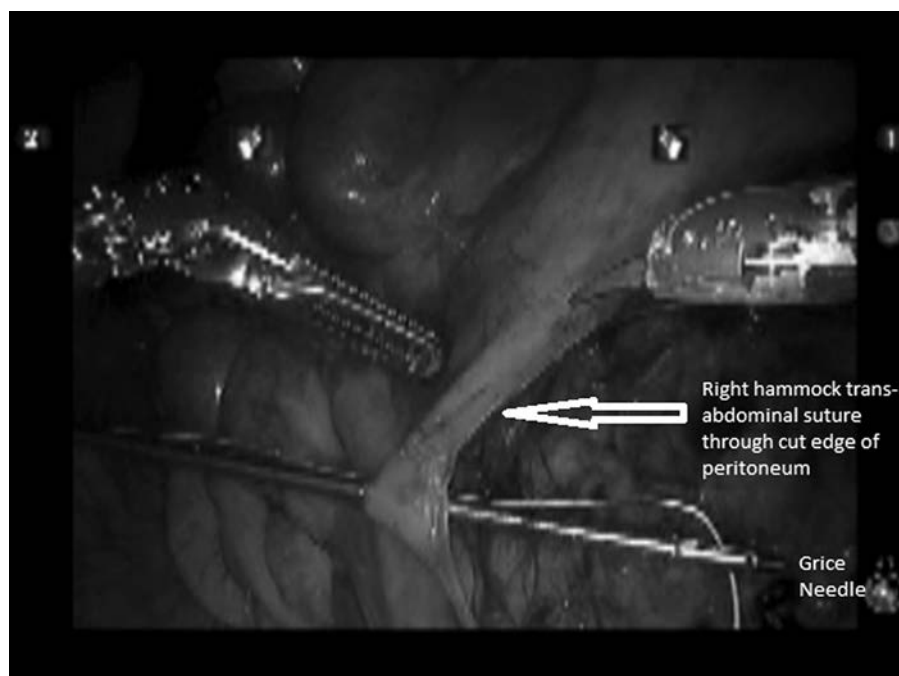


Figure 4. Placement of hammock sutures on one side of the posterior peritoneum. There is an additional hammock suture placed on the other side of the cut edge of the posterior peritoneum to create a curtainlike effect and access to the retroperitoneum.

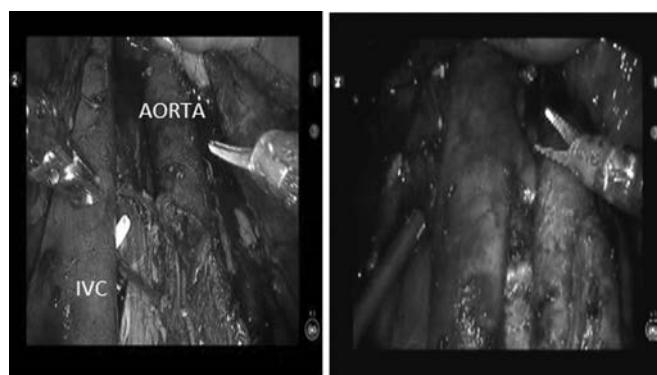


Figure 5. Completion of lymph node dissection. The third robotic arm lifts the duodenum anteriorly while the hammock sutures hold the peritoneum to either side. This allows for a tentlike structure that holds the bowel in its normal anatomical location, while the surgeon works underneath the abdominal contents. IVC, inferior vena cava.

Twelve patients underwent primary (staging) template dissections, while 4 underwent postchemotherapy full bilateral template dissections. The mean operative time was 357 minutes (range 233–716 minutes) with an average estimated blood loss of 205 mL (range 25–450 mL). Patients used on average 47.1 mg morphine equivalents (range 0–179 mg). Postoperatively, the patients stayed in

the hospital for a mean of 3.6 days (range 2–6 days). In addition, the mean number of lymph nodes sampled was 26.2. On average, the patients were ready for discharge by hospital day 2 or 3, but many patients were held for social reasons based on patient disposition at a military treatment facility.

Complications

There were no intraoperative complications or conversions using the inferior approach for the robotic RPLND group of patients. Of note, 1 patient was readmitted with a Clavien IB complication for pancreatitis that resulted in a increased hospital stay of approximately 1 week with no additional sequela.

Outcomes

With early follow-up of over 25 months, there have been no recurrences in either group.

DISCUSSION

Since its inception in 1992,^{9,10} laparoscopic RPLND has been shown to be technically feasible, safe, and efficacious in experienced hands.^{9,11,12} However, questions remain about the oncologic efficacy and applicability of this

technique in the larger community. Minimally invasive RPLND has the potential to reduce the morbidity of surgery for treatment of testicular cancer, while maintaining excellent cancer control.^{9,11} Despite its apparent advantages, laparoscopic RPLND remains controversial. It is a technically challenging procedure that requires a number of cases to develop proficiency—a skill set that is not easily acquired. However, with the advent of robotic-assisted surgery, surgeons can substitute the robot for standard laparoscopy and can enjoy 3-dimensional visualization, increased degrees of freedom, and relief of tremor.⁹ These advantages, along with increasing robotic experience, appear to mitigate some of the technical challenges seen with standard laparoscopy.

With all the advancements in robotic surgery, refinements continue to be made to optimize the robotic platform. In reviewing our case series, there were various learning points. When we decided to use the da Vinci robot for RPLNDs, our goal was to keep the patient positioned for a possible bilateral template. We felt that the supine position offered a more adaptable construct of the anatomy for the robotic surgeon while proceeding with the case. Originally, we conducted our series with the robot docked between the patient's legs with use of a spreader bar. This allowed us full access to the entire retroperitoneum but limited, at times, access to the renal hilum and upper portion of the dissection. With the robot docked between the patient's legs, the robotic arms were superior to the renal hilum. One of the challenges in using this approach was that we needed to have the entire pelvis and abdomen devoid of bowel. This dictated that the small bowel be tucked underneath the diaphragm. This was effective but was limiting when dissecting near the diaphragm and the hilum, as various factors limited proper exposure for dissection. The first limiting factor by using the suprahilar approach was getting the bowel tucked underneath the diaphragm without interfering with retroperitoneal visibility by drifting into our field of view. The second limitation was with the patient's costal margin. The trocars needed to be immediately subcostal. This placed the robotic arms directly anterior to the planned area of dissection, constricting the robotic arm movement, as they were clashing with the costal margin. Given anatomic variation from patient to patient, this effect could never be completely planned for or mitigated. Additionally, by proceeding with a suprahilar approach, despite the fact that there were no duodenal injuries, we felt that the duodenum was placed under compression from the weight of the working robotic arms.

Dr Castle and colleagues at the Mayo Clinic developed an approach by creating the necessary working space by an

inferior approach. They were able to approach the retroperitoneal dissection from an inferior approach by dissecting underneath the root of the small bowel mesentery. This maneuver significantly removed the hindrance of the small bowel and costal margin when trying to place the bowel underneath the diaphragm as well as removing the clashing of the robotic arms with the costal margin while dissecting near the renal hilum. By making this change, the robotic arms are placed more distal, and dissection proceeds from an inferior to superior fashion allowing better visualization of the renal hilum and full access to a retroperitoneal template. This also afforded more maneuverability and visibility throughout the dissection. The third arm provides retraction and consistent exposure to the most difficult part of the operation, which is the superior hilar dissection. After our original series, we decided to proceed with this approach and the placement of the robot 15° off the patient's left shoulder (**Figure 6**).

In addition to a change in robot docking, we believe that the creation of bilateral retroperitoneal windows that are curtained using hammock sutures helps optimize the procedure for both the surgeon and assistant. These hammock sutures are placed within the cut edge of peritoneum and curtain open the retroperitoneum. By using this modification, the small bowel was able to remain suspended anteriorly to the working space in the retroperitoneum and the superior mesenteric artery and duodenum are under far less tension.

In 1992, Clavien and associates^{7,8} proposed and validated a standardized categorization of complications after general surgical procedures in an attempt to minimize the subjectivity in reporting and classifying a complication. This novel Clavien classification grades from I through V and has been adopted into the urologic community over the past 5 years. Despite the low sample size, the morbidity

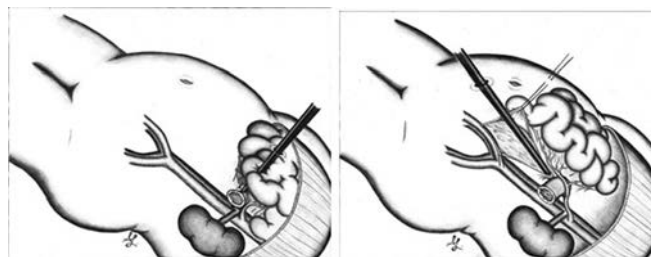

Figure 6. Comparison of the superior (**A**) with the inferior (**B**) approach. Note that with the superior approach, the bowel all needs to be mobilized under the diaphragm. With the inferior approach, however, the instruments work underneath the bowel, which is allowed to rest in a near normal anatomical position.

ity and complication rates from our initial series are low. Since making the change in robotic docking from below, we have had no conversions or major complications, and we feel that the enhanced visibility at the renal hilum by changing the docking of the robot mitigated many potential complications that loom during this portion of the procedure.

Regardless of which technique is used, we believe that robotic RPLND with further studies will provide the same oncological outcomes. Originally, Stephenson and Klein¹³ reported that laparoscopic RPLND should be used only as a staging procedure and not as a therapeutic procedure. However, Guzzo and Allaf,¹⁴ in their series, reported that laparoscopic RPLND can be accepted as a therapeutic option and not just used as a staging procedure. Albqami and Janetschek⁴ demonstrated through an extensive quality of life study that patient satisfaction was higher with laparoscopic RPLND than with open RPLND. Even though it is indeed a difficult technical procedure to perform, we feel that once the long and steep learning curve has been overcome, operative times will approach those of open surgery, with better patient satisfaction in postoperative care management. The reality is that there is no group of patients in whom the benefits of minimally invasive surgery are more pronounced. In addition, there are few procedures where gross inspection of the surgical field can easily point out the adequacy or inadequacy of tissue removal.

The limitations of this study are that this is a retrospective analysis with all the inherent limitations of such a study. There is no long-term (>5 years) follow-up reported. However, it is widely accepted that testicular cancer recurrences usually occur within the first 2 years following diagnosis. In addition, there are no data presented comparing this approach to alternative approaches. A complex analysis needs to be performed looking at the effects not only of surgery, but also of surveillance and chemotherapy in a specialized setting such as a military environment, where getting patients back to their work environment quickly and safely is of paramount importance.

CONCLUSIONS

Robotic-assisted RPLND is feasible for experienced robotic surgeons and potentially minimizes morbidity in an otherwise highly morbid procedure, while maintaining oncologic principles and outcomes. The supine position affords excellent exposure to both sides of the retroperitoneum and allows for safe and meticulous dissection. Further studies looking at long-term results are warranted and ongoing.

References:

1. Yoon GH, Stein JP, Skinner DG. Retroperitoneal lymph node dissection in the treatment of low-stage nonseminomatous germ cell tumors of the testicle. *Expert Rev Anticancer Ther*. 2005;5(1):75–85.
2. Atalla MA, Woodard EJ, Kavoussi LR. Complications of laparoscopic retroperitoneal lymph node dissection. In: *Complications of Laparoscopic and Robotic Urologic Surgery*. Ed. Reza Ghauamian. New York, NY: Springer; 2010:171–176.
3. Bosl GJ, Bajorin DF, Sheinfeld J. Cancer of the testis. In: DeVita VT, Hellman S, Rosenberg SA, eds. *Cancer, Principles and Practice of Oncology*. 7th ed. Philadelphia, PA: Lippincott Williams and Wilkins; 2005:1269–1293.
4. Albqami N, Janetschek G. Laparoscopic retroperitoneal lymph node dissection in the management of clinical stage I and II testicular cancer. *J Endourol*. 2005;19(6):683–692.
5. Annerstedt M, Gudjonsson S, Wult B, et al. Robot-assisted laparoscopic retroperitoneal lymph node dissection in clinical stage II testicular cancer *J Robotic Surg*. 2008;2:189–191.
6. Allaf ME, Bhayani SB, Link RE, et al. Laparoscopic retroperitoneal lymph node dissection: duplication of open technique. *Urology*. 2005;65(3):575–577.
7. Clavien PA, Sanabria JR, Strasberg SM. Proposed classification of complications of surgery with examples of utility in cholecystectomy. *Surgery*. 1992;111(5):518–526.
8. Dindo D, Demartines N, Clavien PA. Classification of surgical complications: a new proposal with evaluation in a cohort of 6336 patients and results of a survey. *Ann Surg*. 2004;240(2):205–213.
9. Davol P, Sumfest J, Rukstalis D. Robotic-assisted laparoscopic retroperitoneal lymph node dissection. *Urology*. 2006; 67(1):199.
10. Ruksatlis DB, Chodak GW. Laparoscopic retroperitoneal lymph node dissection in a patient with stage 1 testicular carcinoma. *J Urol*. 1992;148(6):1907–1910.
11. Steiner H, Peschel R, Janetschek G, et al. Long-term results of laparoscopic retroperitoneal lymph node dissection: a single-center 10-year experience. *Urology*. 2004;63(3):550–555.
12. Gerber GS, Bissada NK, Hulbert JC, et al. Laparoscopic retroperitoneal lymphadenectomy: multi-institutional analysis. *J Urol*. 1994;152(4):1188–1192.
13. Stephenson AJ, Klein EA. Surgical management of low-stage nonseminomatous germ cell testicular cancer. *BJU Int*. 2009; 104(9 Pt B):1362–1368.
14. Guzzo TJ, Allaf ME. Laparoscopic retroperitoneal lymph node dissection for stage I and II nonseminomatous germ-cell tumors. *Ther Adv Urol*. 2009;1(2):107–114.