

# Biliary Stricture After a Roux-en-Y Gastric Bypass with Remnant Gastrectomy

Salvador Navarrete Llopis, MD, Igor Bello, MD, José Luis Leyba, MD, Gabriel Escalona, MD, Cono Gumina

Department of General Surgery, Hospital Universitario de Caracas, Venezuela (Drs. Llopis, Escalona).

Department of General Surgery, Universidad de Carabobo, Nagueagua, Venezuela (Dr. Bello).

Department of General Surgery, Universidad Central de Venezuela, Caracas, Venezuela (Dr. Leyba).

Department of Gastroenterology, Clínica Santa Sofía, Caracas, Venezuela (Dr. Gumina).

## ABSTRACT

**Introduction:** We report a case of benign biliary stricture in a 62-year-old woman after a laparoscopic Roux-en-Y gastric bypass with remnant gastrectomy as a result of morbid obesity and villous adenoma of the gastric antrum.

**Case Description:** The patient's clinical presentation was intermittent biliary-type pain. On admission, no remarkable physical findings were observed, but a dilated common bile duct was seen on a magnetic resonance cholangiography without the presence of stones or tumor masses.

After a failed laparoscopic-assisted endoscopic papillotomy, the case was resolved by a laparoscopic choledocoduodenostomy.

**Discussion:** The diagnosis and treatment of abdominal pain in patients with Roux-en-Y gastric bypass anatomy can be very demanding. Biliary stricture is an infrequent complication in these patients and although the combined approach (endoscopy-laparoscopy) is the initial therapeutic option, a bilioenteric bypass could be required if there are failures or relapses.

**Key Words:** Roux-en-Y gastric bypass, Biliary stricture, Laparoscopy.

**Citation** Llopis SN, Bello I, Leyba JL, Escalona G, Gumina C. Biliary stricture after a Roux-en-Y gastric bypass with remnant gastrectomy. CRSLS e2014.00308. DOI: 10.4293/CRSLS.2014.00308.

**Copyright** © 2014 SLS. This is an open-access article distributed under the terms of the Creative Commons Attribution-Noncommercial-ShareAlike 3.0 Unported license, which permits unrestricted noncommercial use, distribution, and reproduction in any medium, provided the original author and source are credited.

Address correspondence to: José Luis Leyba, MD, Department of General Surgery, Universidad Central de Venezuela, Caracas, Venezuela. E-mail address: jlleyba@yahoo.es

## INTRODUCTION

Bariatric surgery is currently the most effective way to treat patients with morbid obesity, and Roux-en-Y gastric bypass (RYGB) is one of the techniques that provides better results and has greater acceptance by patients and surgeons.<sup>1</sup>

Bariatric procedures are one of the most common gastrointestinal operations performed around the world, and in 2011, RYGB remained the most used bariatric technique.<sup>2</sup>

The increase in this practice also increases the treatment of patients with abdominal pain and a history of RYGB. Between 15% and 30% of patients will visit the emergency

department within the first three years of undergoing gastric bypass, and abdominal pain is the primary complaint in more than half of these cases.<sup>3</sup>

The changes in the gastrointestinal anatomy after RYGB increase the difficulty in the diagnosis of abdominal pain, and in some cases they also increase the complexity of surgical treatment, generating major challenges, especially if the surgeon is unfamiliar with bariatric surgery.<sup>4,5</sup>

We report the approach to a patient with a history of RYGB and remnant gastrectomy with acute postprandial abdominal pain whose definitive diagnosis was benign stricture of the distal main bile duct.

## CASE REPORT

In February 2011, a 62-year-old female patient underwent laparoscopic RYGB and remnant gastrectomy to treat morbid obesity (body mass index 40.5 kg/m<sup>2</sup>) and villous adenoma of the gastric antrum.

In summary, the *RYGB* technique consisted of a 30-mL gastric pouch with the lesser curvature, a 50-cm bilio-pancreatic limb, a 150-cm antecolic alimentary limb, end-side gastrojejunostomy using a cutting endolinear stapler, side-to-side jejunojunctionostomy using a cutting endolinear stapler, and closure of the mesenteric defects. The remnant gastrectomy was completed by sectioning the duodenum with an endolinear stapler after devascularization of the entire greater curvature, the gastric fundus, and part of the lesser curvature with an ultrasonic scalpel.

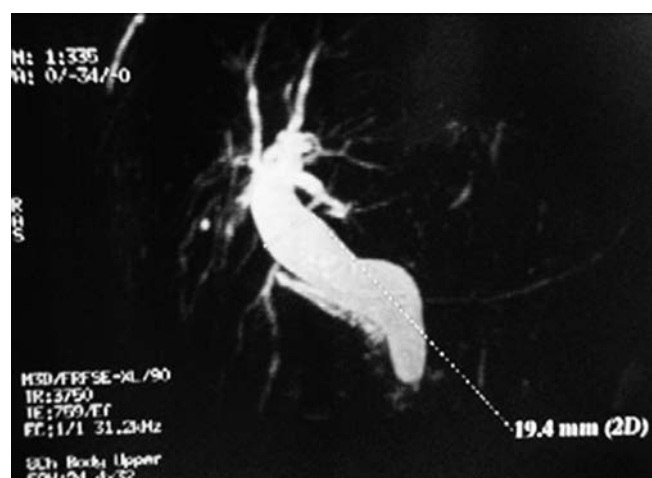Initially, the patient showed favorable progress, but 7 months postoperatively she began to have intermittent postprandial abdominal pain in the epigastrium and right upper quadrant, with dyspepsia, nausea, and vomiting.

On physical examination, there were no abnormal findings, and laboratory tests such as serum amylase, lipase, excretion liver tests (bilirubin, gamma-glutamyl transpeptidase, alkaline phosphatase), and tumor marker (CEA, CA 125, and CA 19–9) levels revealed normal values.

An upper digestive endoscopy showed a normal gastric pouch and gastrojejunal anastomosis, whereas abdominal ultrasonography revealed an absent gallbladder (history of open cholecystectomy 20 years prior) and common bile duct dilatation to 18 mm.

Magnetic resonance cholangiopancreatography was performed and showed a dilatation of the common bile duct to 19 mm with a sudden decrease in its distal diameter and a normal main pancreatic duct (**Figure 1**). Computed tomography showed no pancreatic or periampullary tumor mass.

We attempted to perform a retrograde cholangiopancreatography via double-balloon enteroscopy but were not able to access the second portion of the duodenum because of the long limb created in the bypass surgery. Thus we decided to perform a retrograde cholangiopancreatography using a combined approach: laparoscopic and endoscopic. First, we performed a laparoscopic approach, followed by an enterotomy of the biliopancreatic limb and, finally, an enteroscopy through it to access the am-



**Figure 1.** Magnetic resonance cholangiopancreatography showing dilatation of the common bile duct.

pulla of Vater was possible, doing the sphincterotomy with biopsy. During the laparoscopy, we evaluated the anatomy of the RYGB and ruled out the presence of internal hernias.

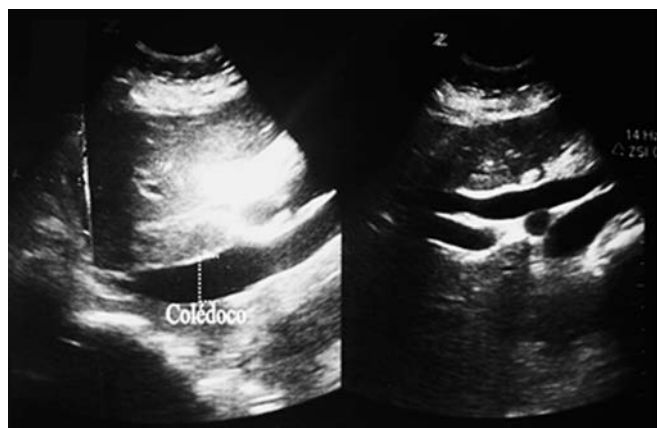
The histopathological study revealed destruction of the mucosa and replacement of the sphincter muscle tissue with dense connective tissue, with infiltration of lymphocytes and plasma cells and without evidence of malignancy.

The patient remained asymptomatic for 6 months, after which she presented with abdominal pain with the same characteristics. She was assessed again and her liver excretion test (bilirubin, gamma-glutamyl transpeptidase, alkaline phosphatase), and tumor markers (CEA, CA 125, and CA 19–9) levels were again normal.

Abdominal ultrasonography showed persistent dilation of the common bile duct to 21 mm (**Figure 2**), and magnetic resonance cholangiography showed a common bile duct dilated to 22 mm at the proximal segment, with a sudden reduction in its diameter in the intraduodenal portion (**Figure 3**).

Confirming a diagnosis of benign biliary stricture of the distal common bile duct, we decided to treat the patient by performing a laparoscopic bilioenteric bypass.

A second laparoscopy was performed in November 2012, and the surgical findings were a dilated extrahepatic bile duct, >2 cm, a duodenal stump with mild adhesions, and a RYGB with closed mesenteric spaces (Petersen and intermesenteric). A laparoscopic side-to-side choledocoduodenostomy was performed with 4–0



**Figure 2.** Abdominal ultrasonogram showing evidence of persistent important dilation of the common bile duct.

polyglactin interrupted stitches in a single layer (**Figure 4**).

The patient recovered satisfactorily and was discharged on the fourth postoperative day with no complications. She remains asymptomatic after 18 months.

## DISCUSSION

By 2011, 340 768 bariatric procedures had been performed globally, RYGB being the most common technique (46.6%).<sup>2</sup>

Although the benefits of this surgery are clear, the anatomical changes that it creates predispose the patient to new morbidities, including conditions with a significant risk of mortality.<sup>3,5</sup>

Although confirming the differential diagnosis of abdominal pain after a RYGB can take time and may originate from unrelated conditions, it must initially include three pathologies: gallstones, internal hernias, and ulcer disease.<sup>5–9</sup>

These pathologies may share common symptoms (postprandial abdominal pain, nausea, vomiting, and distention) and the physical examination may provide few data, so we included abdominal ultrasonography and an upper digestive endoscopy as complementary studies in our initial assessment.

If these studies rule out gallstones or ulcer disease, an internal hernia should be considered, especially if the mesenteric defects were not closed during the initial surgery.<sup>5,10</sup>

In this case, the dilatation of the bile duct seen with ultrasonography, the history of cholecystectomy 20 years prior, and the normal endoscopy initially aimed the diagnosis toward a distal biliary obstruction. In addition, periampullary tumor pathology and common duct stones were ruled out after computed tomography and magnetic resonance cholangiography.

Our proposed diagnosis based on these findings was stenosis of the terminal portion of the common bile duct caused by sphincter of Oddi dysfunction (SOD) or an iatrogenic lesion associated with the remnant gastrectomy during the RYGB.

Although the benign stricture of extrahepatic bile duct after bariatric surgery has been reported as SOD by Morgan et al,<sup>11</sup> it may also occur as an iatrogenic injury after distal gastrectomy.<sup>12</sup>

Devascularization of the terminal common bile duct during the mobilization and duodenal section of the gastrectomy may cause an inflammatory process that ends in a stricture at that level, with the consequent proximal dilatation by obstruction.

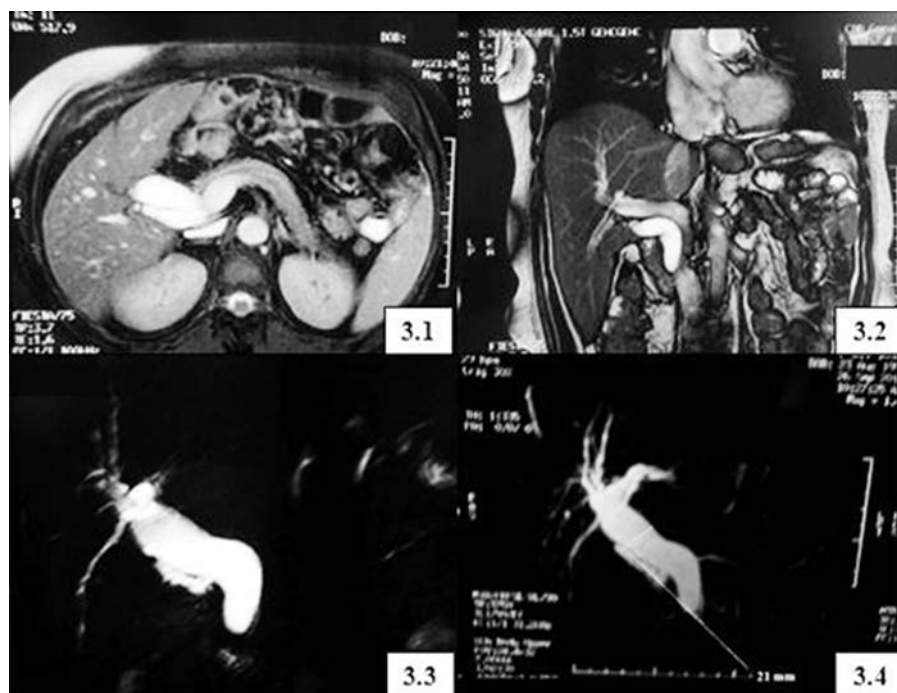
Currently, secretin-stimulated magnetic resonance cholangiopancreatography and SOD manometry are the most used diagnostic methods for SOD, none of which were available to us, so we were not able to dismiss this possibility, specifically a SOD type II according to the Milwaukee classification.<sup>13</sup>

Although the remnant gastrectomy during a gastric bypass is not a routine procedure, it may be indicated in the case of a benign gastric tumor or in patients at high risk for gastric cancer. In these cases, the patient may also develop complications inherent to the gastrectomy besides those derived from the bariatric procedure itself.

The approach of the ampulla of Vater after an RYGB usually takes place through the gastric remnant, assisted by laparoscopy, or percutaneously if a gastrostomy was made in the original procedure.<sup>14,15</sup>

In RYGB patients, the endoscopic retrograde cholangiopancreatography is undoubtedly an arduous and difficult process, which is more evident in cases where the alimentary limb is longer. Access to the ampulla of Vater in patients with Billroth type or RYGB is associated with a higher rate of failure and complications, especially duodenal perforations.<sup>16–19</sup>

In our patient, the remnant gastrectomy forced our attempt to access the ampulla of Vater via enteroscopy, which failed because the gastroenterologist could not ac-



**Figure 3.** Magnetic resonance cholangiography showing a dilated common bile duct, without the presence of stones or tumor masses. 3.1, Axial view; 3.2, coronal view; 3.3 and 3.4, reconstruction.

cess the duodenum. Thus we decided on a combined approach, practicing a laparoscopy to perform the study through the biliopancreatic limb.

Although the sphincterotomy was performed this way, it was not satisfactory because the patient's symptoms recurred after 6 months. Despite this, tumor pathology was discarded through the papillary biopsy.

The final resolution was performed via a bilioenteric bypass, via a laparoscopic side-to-side choledocoduodenostomy, which relieved her symptoms without new episodes of abdominal pain during her 18-month follow-up.

We conclude that benign strictures of the biliary system are a challenging clinical problem in patients with gastrointestinal anatomic modifications like those who have undergone RYGB. Although the combined approach (endoscopy-laparoscopy) is the initial therapeutic option, the condition must be solved surgically if there are failures or relapses, as had occurred in our patient.

## References:

1. Picot J, Jones J, Colquitt JL, et al. The clinical effectiveness and cost effectiveness of bariatric (weight loss) surgery for mor-

- bid obesity: a systematic review and economic evaluation. *Health Technol Assess.* 2009;13:1–190.

2. Buchwald H, Oien DM. Metabolic/bariatric surgery worldwide 2011. *Obes Surg.* 2013;23:427–436.

3. Greenstein AJ, O'Rourke RW. Abdominal pain after gastric bypass: suspects and solutions. *Am J Surg.* 2011;201:819–827.

4. Nikfarjam M, Staveley-O'Carroll KF, Kimchi ET, et al. Pancreaticoduodenectomy in patients with a history of Roux-en Y gastric bypass surgery. *JOP.* 2009;10:169–73.

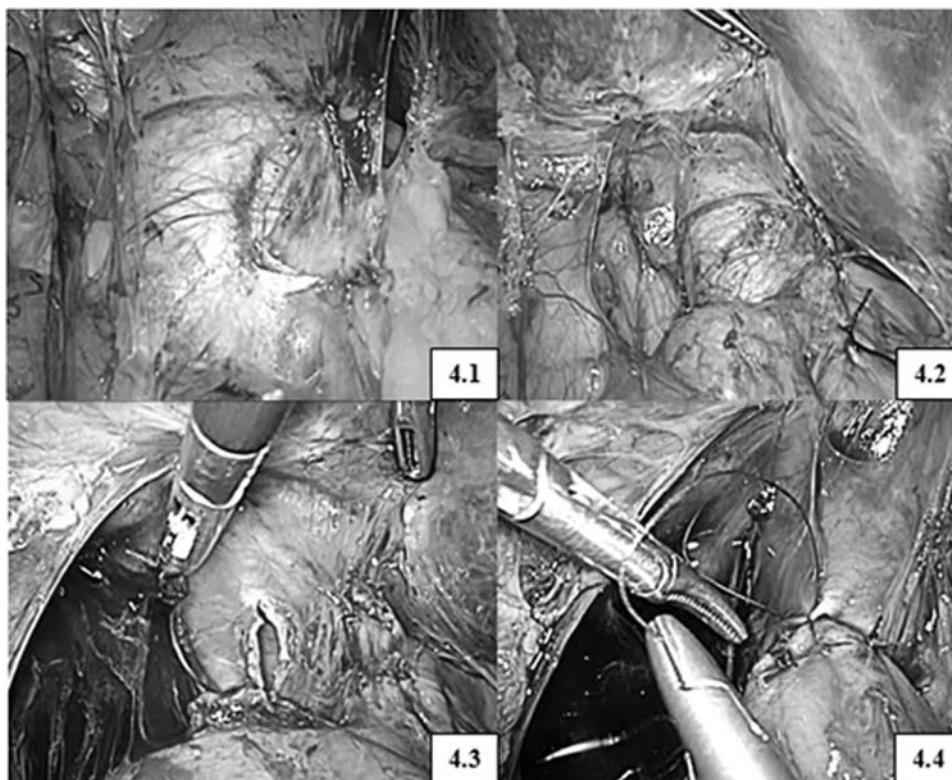
5. Leyba JL, Navarrete S, Navarrete Llopis S, et al. Laparoscopic technique for hernia reduction and mesenteric defect closure in patients with internal hernia as a postoperative complication of laparoscopic Roux-en-Y gastric bypass. *Surg Laparosc Endosc Percutan Tech.* 2012;22:e182–e185.

6. Hope WW, Sing RF, Chen AY, et al. Failure of mesenteric defect closure after Roux en Y gastric bypass. *JSLS.* 2010;14:213–216.

7. Li VK, Pulido N, Fajnwaks P, et al. Predictor of gallstone formation after bariatric surgery: a multivariate analysis for risk factors comparing gastric bypass, gastric banding, and sleeve gastrectomy. *Surg Endosc.* 2009;23:1640–1644.

8. Campanile FC, Boru CE, Rizzello M, et al. Acute complications after laparoscopic bariatric procedures: update for





**Figure 4.** Laparoscopic side-to-side choledocoduodenostomy. 4.1, Dilated common bile duct; 4.2, dilated common bile duct and duodenal stump; 4.3, choledocotomy; 4.4, choledocoduodenostomy with interrupted stitches.

the general surgeon. *Langenbecks Arch Surg.* 2013;398:669–686.

9. Sidani S, Akkary E, Bell R. Catastrophic bleeding from a marginal ulcer after gastric bypass. *JSLs.* 2013;17:148–151.

10. Leyba JL, Navarrete Aulestia S, Navarrete Llopis S, et al. Hernias internas luego de bypass gástrico en Y de Roux por laparoscopia. *Revista de la Facultad de Medicina.* 2011;34:51–54.

11. Morgan KA, Glenn JB, Byrne TK, et al. Sphincter of Oddi dysfunction after Roux-en-Y gastric bypass. *Surg Obes Relat Dis.* 2009;5:571–575.

12. Dixon JA, Morgan KA, Adams DB, et al. Management of common bile duct injury during partial gastrectomy. *Am Surg.* 2009;75:719–721.

13. Green JE, Hogan WJ, Doods WJ, et al. The efficacy of endoscopic sphincterotomy after cholecystectomy in patients with sphincter of Oddi dysfunction. *N Engl J Med.* 1989;320:82–87.

14. Nguyen NT, Hinojosa MW, Slone J, et al. Laparoscopic transgastric access to the biliary tree after Roux-en-Y gastric bypass. *Obes Surg.* 2007;17:416–419.

15. Falcão M, Campos JM, Galvão Neto M, et al. Transgastric endoscopic retrograde cholangiopancreatography for the management of biliary tract disease after Roux-en-Y gastric bypass treatment for obesity. *Obes Surg.* 2012;22:872–876.

16. Lin LF, Siau CP, Ho KS, et al. ERCP in post-Billroth II gastrectomy patients: emphasis on technique. *Am J Gastroenterol.* 1999;94:144–148.

17. Hintze RE, Adler A, Veltzke W, et al. Endoscopic access to the papilla of Vater for endoscopic retrograde cholangiopancreatography in patients with billroth II or Roux-en-Y gastrojejunostomy. *Endoscopy.* 1997;29:69–73.

18. Chahal P, Baron TH, Topazian MD, et al. Endoscopic retrograde cholangiopancreatography in post-Whipple patients. *Endoscopy.* 2006;38:1241–1245.

19. Koshitani T, Matsuda S, Takai K, et al. Direct cholangioscopy combined with double-balloon enteroscope-assisted endoscopic retrograde cholangiopancreatography. *World J Gastroenterol.* 2012;18:3765–3769.