

# Totally Laparoscopic Transhiatal Approach to Resection of a Lower Esophageal Posterior Mediastinal Foregut Duplication Cyst

Scott Wessner, DO, Nicholas Houlis, DO, Sathyaprasad Burjonrappa, MD, MS, FRCS(Ed), FACS

Department of Surgery, St. Joseph's Regional Medical Center, Paterson, NJ, USA (all authors).

Department of Surgery, Childrens Hospital of New Jersey, Maplewood, NJ, USA (Dr. Burjonrappa).

## ABSTRACT

Management of intrathoracic foregut duplication cysts has traditionally involved a thoracotomy. Recently thoracoscopic approaches have been successfully described in the management of this condition. We describe the first laparoscopic transhiatal approach to the management of an intrathoracic duplication cyst in the pediatric population.

**Key Words:** Esophageal duplication cyst, Foregut duplication cyst, Laparoscopy; Transhiatal.

**Citation** Wessner S, Houlis N, Burjonrappa S. Totally laparoscopic transhiatal approach to resection of a lower esophageal posterior mediastinal foregut duplication cyst. CR<sup>SLS</sup> e2014.00295. DOI: 10.4293/CR<sup>SLS</sup>.2014.00295.

**Copyright** © 2014 SLS This is an open-access article distributed under the terms of the Creative Commons Attribution-Noncommercial-ShareAlike 3.0 Unported license, which permits unrestricted noncommercial use, distribution, and reproduction in any medium, provided the original author and source are credited.

Address correspondence to: Sathyaprasad Burjonrappa MD, MS, FRCS(Ed), FACS, Attending Pediatric Surgeon, 2130 Millburn Avenue, Suite C-1, Maplewood, NJ 07040. Telephone: 973-313-3115, Fax: 718-576-3578, E-mail: sathyabc@yahoo.com

## INTRODUCTION

Bronchogenic cysts are the most common cystic masses diagnosed in the thorax.<sup>1-5</sup> They result from abnormal development of the embryonic foregut during the fifth to eighth week of gestation.<sup>1,6,7</sup> Bronchogenic cysts were classically considered an isolated entity from other embryologic anomalies, such as esophageal duplications and neurenteric cysts, but given their common embryologic origin, histology, and anatomic locations, they are now known collectively as foregut duplication cysts.<sup>1,6</sup>

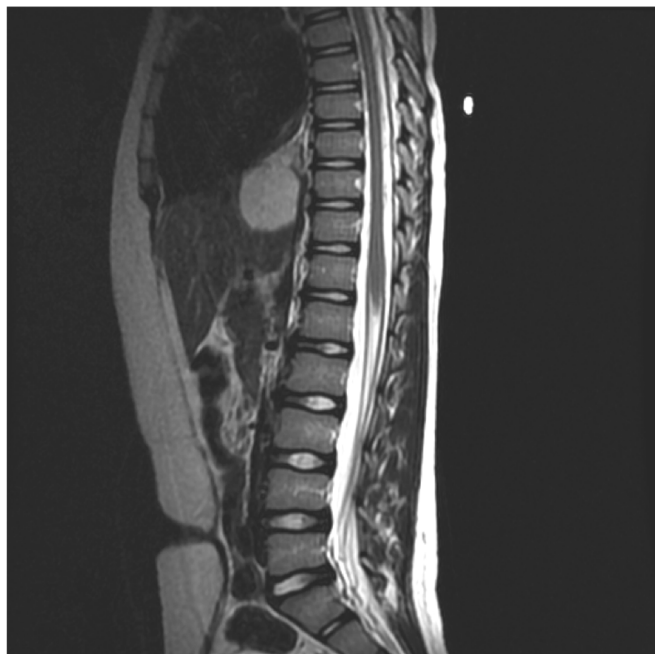Thoracotomy is the standard approach for excision of thoracic foregut duplications, although minimal-access thoracoscopy has progressively increased in popularity.<sup>8</sup> There are few reports of the laparoscopic approach to mediastinal foregut duplications. Avoiding the thoracic approach has the advantage of avoiding one-lung ventilation during the case; placement of a tube thoracostomy; and the potential for decreased operative stress, pain, and number of hospital days.<sup>8-10</sup> Here, we present a novel approach to a posterior mediastinal foregut duplication in an 11-year-old boy, using a totally laparoscopic transhiatal procedure, with good results.

## CASE REPORT

The patient was an 11-year-old boy, 30 kg, who was incidentally diagnosed with a mediastinal mass during his preoperative workup for resection of a malignant cerebellopontine ependymoma. A 4.5-cm complex, nonenhancing, cystic structure was found in the posterior mediastinum on magnetic resonance images. It coursed along the distal esophagus straddling the diaphragm, adjacent to the left lobe of liver, with the superior margin abutting the left atrium (**Figure 1**). A gastrostomy was placed to improve his nutrition and facilitate recovery from the adjuvant chemoradiotherapy that followed ependymoma excision. Subsequent magnetic resonance imaging showed some extension of the mediastinal mass toward the gastroesophageal junction with compression and displacement of the esophagus. After several weeks of recovery from chemoradiation therapy, he was scheduled for a laparoscopic mass excision.

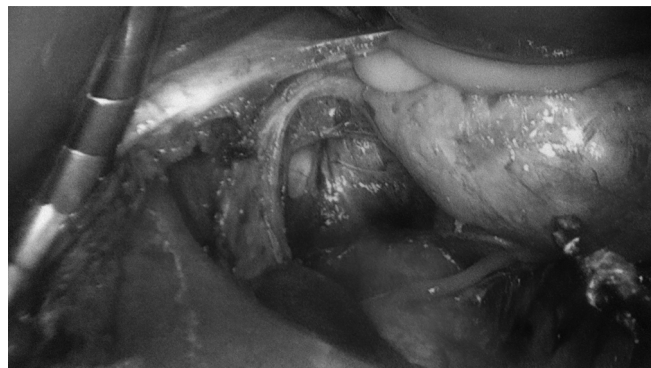
### Surgical Procedure

The patient was placed in the supine position on the operating table. Five 5-mm trocars were placed: 1 near the umbilicus, 2 in the epigastrium on either side of the midline as working ports, and 1 right and 1 left subcostal for retraction. After retracting the liver, an abnormal mass was seen



**Figure 1.** Magnetic resonance image showing posterior mediastinal cyst extending to the inferior cardiac border.

bulging through the esophageal hiatus displacing the vena cava. The intra-abdominal esophagus was isolated with an umbilical tape. We exposed the intrathoracic esophagus by opening the diaphragmatic hiatus. The cyst was first dissected laterally off its attachment to the vena cava using the hook cautery. Posteriorly, the cyst was dissected from the aorta and paravertebral musculature (**Figure 2**). The right vagus nerve was displaced away from the esophagus onto the aorta and was carefully preserved. The inferior aspect of the neck of the cyst was defined by performing a myotomy of the distal esophagus, and this plane was carefully developed along its sides. To facilitate mediastinal mobilization near the inferior pulmonary vein and right atrium, the cyst was decompressed. Circumferential mobilization of the cyst indicated that the neck of the cyst was closer to the hiatus than we initially anticipated. A 38F bougie was passed into the stomach to calibrate the esophagus prior to resecting the mass with a 45-mm Endo GIA (Covidien, Mansfield, MA) (placed through an up-sized 12-mm trocar in the epigastrium). An endopouch bag was used to remove the specimen from the operative field. An intraoperative upper endoscopy confirmed the integrity of the mucosal layer of the esophagus. The previously opened diaphragmatic hiatus was repaired and an anterior Dor (180°) fundoplication was performed to cover the myotomy site, which now extended 3-cm intra-abdominally. There was no postoperative pneumothorax.



**Figure 2.** Intraoperative picture showing duplication cyst that has been rotated to the left of the patient. The cyst (left of image) has been dissected away from its superior attachments within the chest leaving it attached to the lower esophagus. The inferior vena cava (right of hiatus) and aorta (posterior bed of hiatus) are visualized along with the enlarged esophageal hiatus. The cyst was decompressed after mobilization to facilitate stapler application and the contents were cream yellow in color and mucinous in consistency (seen toward the top left).

The child tolerated the procedure well. On postoperative day 3, an upper gastrointestinal series was performed and showed no leak or stricture of the esophagus. He was started on a clear liquid diet supplemented with gastrostomy tube feeds. On postoperative day 7, he was tolerating a soft oral diet and was discharged. The final pathology was consistent with a bronchogenic cyst consisting of respiratory type, ciliated columnar epithelium, containing cartilage in the wall. The child has since been seen at his 1-year follow-up appointment and is doing well with complete resolution of the dysphagia.

## DISCUSSION

Foregut duplications are rare congenital abnormalities originating from errors in embryologic development.<sup>11</sup> Duplication cysts may arise from aberrant budding of the tracheobronchial tree, abnormal separation of the primitive trachea and esophagus, or the persistent adherence of the endoderm to the notochord.<sup>12</sup> Bronchogenic cysts are characteristically lined with ciliated columnar epithelium and contain seromucinous glands and hyaline cartilage while esophageal duplications usually contain gastric, esophageal, or pancreatic mucosa along with 2 layers of smooth muscle within the wall.<sup>1,2,13</sup> They are collectively known as foregut duplication cysts, emphasizing their embryologic, histologic, and anatomic similarities.<sup>1-6,8,9,14,15</sup> Both are most commonly found in the mediastinum and present with symptoms secondary to intrathoracic mass effect or intracystic secretions.<sup>6,11,12</sup>

A retrospective review of 68 cases of foregut duplications discovered a 15% incidence of cysts with a mixture of both respiratory and alimentary tract epithelium, although bronchogenic cysts were still the most common.<sup>6</sup> The clinical implication of a hybrid cyst is the increased potential for acute symptoms due to intracystic gastric or pancreatic secretions leading to ulceration, bleeding, strictures, or perforation.<sup>5,8,12,16</sup>

Diagnosis in the pediatric population is usually between 1 and 4 years, but incidental prenatal diagnosis is made, by ultrasound, in up to one-third of cases, usually between 22 and 27 weeks' gestation.<sup>6,8</sup> The cysts generally measure 1 to 2 cm in diameter at birth and often expand to  $\geq 10$  cm in an adult. Expectant management of foregut duplications is not recommended, as most patients will eventually develop symptoms. Mass-effect and gastrointestinal complaints are the most common symptoms and approximately 50% to 75% of pediatric patients diagnosed with foregut duplications are symptomatic.<sup>1,6,12,17</sup> Symptomatic patients generally have a higher rate of intraoperative complications, including injury to the vagus nerve, incomplete resection, higher rate of conversion from minimally invasive to open surgery, and longer durations of ventilator support and more hospital days.<sup>1,4,6,8,12,15,16,17</sup> Outcomes seem to be improved in patients who are diagnosed prenatally because surgery can be planned at an early age, before symptoms or complications arise.<sup>8</sup> Based on a few case reports, some physicians cite the potential for malignant transformation of foregut duplications as an additional reason for early resection.<sup>1,6,12,18</sup>

Thoracotomy and enucleation is the standard procedure for excision of mediastinal foregut duplications.<sup>2,4,10</sup> Minimal access thoracoscopy has become progressively more common, offering the advantages of reduced postoperative pain, earlier recovery, and fewer hospital days.<sup>8,19</sup> The laparoscopic approach avoids the repercussions of operating through the thorax. This includes the deleterious effects of one-lung ventilation on the immune and respiratory system, as well as the placement of a tube thoracostomy.<sup>10,20</sup> To the best of our knowledge, this is the first report of a totally laparoscopic transhiatal approach to posterior mediastinal foregut duplication in the pediatric population. There are at least 2 reports of laparoscopic excision of intra-abdominal foregut cysts in children,<sup>13,21</sup> and 2 reports of partially laparoscopic resection of mediastinal foregut duplications in adults.<sup>7,16</sup>

The transhiatal laparoscopic approach offers the advantage of avoiding the morbidities associated with thoracic surgery while providing a safe and effective resection. The

laparoscopic approach allowed an excellent visualization of the lesion, safe mobilization of adjacent structures, use a vertical cutting stapler, visualization of both the mediastinal and abdominal compartments to evaluate for additional pathology, and the opportunity to concurrently perform an antireflux procedure. We believe that it is important to correctly define the neck of the cyst and performing a myotomy facilitates this step. It is also important to avoid entering into the cyst while performing the myotomy as the mucosa may bulge irregularly at the cyst-esophagus interface. This step facilitates accurate stapler application. Having a bougie in the esophagus prevents inadvertent narrowing of the lumen during stapler application. Additionally, because we had abdominal access, we were able to perform a fundoplication to protect the myotomy site. We did not take down the previous gastrostomy and were able to satisfactorily work around it. Upper endoscopy was performed intraoperatively to confirm the integrity of the esophageal lumen. We believe that performing the myotomy and calibrating the esophagus has the potential benefits of reducing the incidence of late esophageal leaks, iatrogenic injury, and reoperation for recurrence. This appears to be a safe and feasible alternative to the traditional thoracic approach.

## References:

1. Azzie G, Beasley S. Diagnosis and treatment of foregut duplications. *Semin Pediatr Surg.* 2003;12(1):46–54.
2. Cioffi U, Bonavina L, De Simone M, et al. Presentation and surgical management of bronchogenic and esophageal duplication cysts in adults. *Chest.* 1998;113(6):1492–1496.
3. Ranganath S, Lee E, Restrepo R, Eisenberg R. Mediastinal masses in children. *AJR Am J Roentgenol.* 2012;198(3):W197–W216.
4. Turkyilmaz A, Eroglu A, Subasi M, Findik G. Intramural esophageal bronchogenic cysts: a review of the literature. *Dis Esophagus.* 2007;20(6):461–465.
5. Wang W, Ni Y, Zhang L, et al. A case report of paraesophageal bronchogenic cyst with esophageal communication. *J Cardiothorac Surg.* 2012;7:94.
6. Nobuhara KK, Gorski YC, LA Quaglia MP, Shamberger RC. Bronchogenic cysts and esophageal duplications: common origins and treatment. *J Pediatr Surg.* 1997;32(10):1408–1413.
7. Shiozaki A, Fujiwara H, Murayama Y, Komatsu S, Kuriu Y. Hand-assisted laparoscopic transhiatal approach for mediastinal esophageal duplication cyst resection. *Esophagus.* 2012;9:247–251.
8. Ballouhey Q, Galinier P, Abbo O, et al. The surgical management and outcome of congenital mediastinal malformations. *Interact Cardiovasc Thorac Surg.* 2012;14(6):754–759.

9. Zügel NP, Kox M, Lang RA, Hüttl TP. Laparoscopic resection of an intradiaphragmatic bronchogenic cyst. *JSLS*. 2008;12(3):318–320.
10. Tanaka K, Hara I, Yamaguchi K, Takeda M, Takenaka A, Fujisawa M. Laparoscopic resection of a lower posterior mediastinal tumor: feasibility of using a transdiaphragmatic approach. *Urology*. 2007;70(6):1215–1218.
11. Gun F, Erginel B, Ünüvar A, Kebudi R, Salman T, Celik A. Mediastinal masses in children: experience with 120 cases. *Pediatr Hematol Oncol*. 2012;29(2):141–147.
12. Petroze R, McGahren ED. Pediatric chest II: benign tumors and cysts. *Surg Clin North Am*. 2012;92(3):645–658, ix.
13. Aldrink JH, Kenney BD. Laparoscopic excision of an esophageal duplication cyst. *Surg Laparosc Endosc Percutan Tech*. 2011;21(5):e280–e283.
14. Yang X, Partanen K, Seppä A, Berg E, Pasanen P. Paraesophageal bronchogenic cyst in the adult: can it be differentiated from intramural esophageal cyst by different imaging? Case report and review of the literature. *Clin Imaging*. 1994;18(1):68–71.
15. Kelleher CM, Forcione DG, Gee MS, Mino-Kenudson M. Case records of the Massachusetts General Hospital. Case 10-2012. A 16-year-old boy with epigastric pain and a mediastinal mass. *N Engl J Med*. 2012;366(13):1241–1249.
16. Zdenek K, Vladimír P, Markéta H, Petr K. Partial laparoscopic resection of inflamed mediastinal esophageal duplication cyst. *Surg Laparosc Endosc Percutan Tech*. 2007;17(4):311–312.
17. Bratu I, Laberge JM, Flageole H, Bouchard S. Foregut duplications: is there an advantage to thoracoscopic resection? *J Pediatr Surg*. 2005;40(1):138–141.
18. Liang MK, Yee HT, Song JW, Marks JL. Subdiaphragmatic bronchogenic cysts: a comprehensive review of the literature. *Am Surg*. 2005;71(12):1034–1041.
19. Neo EL, Watson DI, Bessell JR. Acute ruptured esophageal duplication cyst. *Dis Esophagus*. 2004;17(1):109–111.
20. Zingg U, Forberger J, Frey DM, et al. Inflammatory response in ventilated left and collapsed right lungs, serum and pleural fluid, in transthoracic esophagectomy for cancer. *Eur Cytokine Netw*. 2010;21(1):50–57.
21. Pujar VC, Kurbet S, Kaltari DK. Laparoscopic excision of intra-abdominal oesophageal duplication cyst in a child. *J Minim Access Surg*. 2013;9(1):34–36.