

Laparoscopic Cholecystectomy in Patients with Situs Inversus Totalis

Basmah Amin Rafie, MS, MRCS, Omar Jamil AbuHamdan, MS, PhD

Department of General Surgery, Hera General Hospital, Makkah, Kingdom of Saudi Arabia (all authors).

ABSTRACT

Situs inversus totalis (SIT) is a rare congenital anomaly characterized by complete transposition of abdominal and thoracic organs. Change in anatomical disposition of the organs not only influences the location of symptoms and signs arising from a diseased organ, but also imposes special demands on the diagnostic and surgical skills of the surgeon. We discuss two cases of SIT, outline how the diagnoses were made, and describe the pitfalls encountered during the surgery and how they were overcome. Although there is no current evidence supporting the increased incidence of cholelithiasis in patients with SIT, reports have shown that symptomatic gall bladder disease in these patients can be successfully and safely treated laparoscopically.

Key Words: Situs inversus, Laparoscopic cholecystectomy.

Citation Rafie BA, AbuHamdan OJ. Laparoscopic cholecystectomy in patients with situs inversus totalis. CRSLS e2014.00018. DOI: 10.4293/CRSLS.2014.00018.

Copyright © 2014 SLS This is an open-access article distributed under the terms of the Creative Commons Attribution-Noncommercial-ShareAlike 3.0 Unported license, which permits unrestricted noncommercial use, distribution, and reproduction in any medium, provided the original author and source are credited.

Address correspondence to: Basmah Amin Rafie, MS, MRCS, Hera General Hospital, Makkah, Makkah Region, Saudi Arabia. Telephone: (+966) 5555-17645, Fax: (+966) 2-5200333, E-mail: al-rafie@hotmail.com

INTRODUCTION

Situs inversus totalis (SIT) is a very uncommon congenital anomaly characterized by complete transposition of abdominal and thoracic organs to the opposite side of the body in a mirror image of what is normal. As a birth defect in newborn infants, it has an estimated incidence of 1/15 000 to 10 000 cases in live births, with a male/female ratio of 3:2.¹ The cause of situs inversus (SI) is unknown. More than one genetic mutation, including gene mutations that cause ciliopathy and cystic renal diseases, were implicated in its etiopathogenesis.²

There is no evidence to suggest that SI predisposes to cholelithiasis or that cholelithiasis occurs with greater frequency in this population. Similarly, symptoms of gallstone disease probably present with similar frequency in patients with SI as in the general population.³

However, because laparoscopic cholecystectomy is the gold standard in the treatment of symptomatic gallbladder disease, reports have shown that regardless of the etiology of the left-sided gall bladder, cholelithiasis, cholecystitis, and even empyema of the gall bladder in these patients can be successfully and safely treated laparoscopically.⁴

Few cases of laparoscopic cholecystectomy in patients with SI were reported from Saudi Arabia, and the aim of this article is to add our different surgical approach of such rare cases to the literature.⁵⁻⁸

CASE REPORTS

Case 1

A 72-year-old Pakistani woman presented with epigastric pain of a 3-year duration. The pain was colicky, prominent after meals, and had been worsening in the previous few days. She was afebrile and not jaundiced, and the abdominal examination showed tenderness on palpation of her epigastrium and left upper quadrant. Laboratory values revealed mild leukocytosis of 11 000 cells/mL (normal range, 4.8–10.8 thousand cells/mL), and amylase and liver function test results were normal.

A chest radiograph revealed dextrocardia (**Figure 1**). Imaging by ultrasonography and subsequently by magnetic resonance cholangiopancreatography (MRCP), which was done because of the nature of the reversed anatomy and to rule out the possibility of associated anomalies, showed visceral SI with multiple gall stones in a left-sided gall

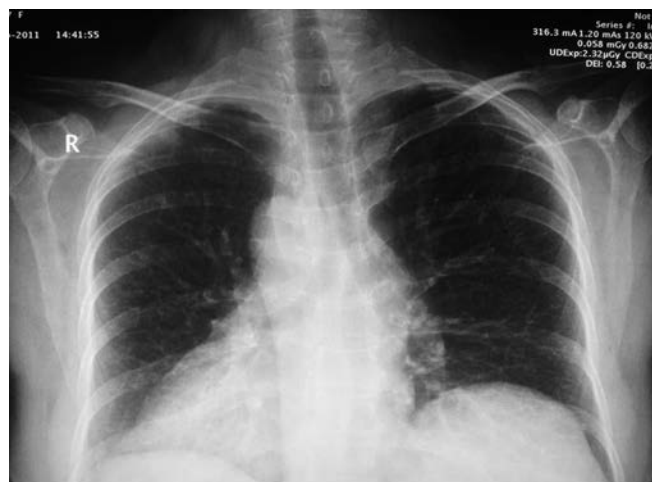

Figure 1. Case 1: Chest radiograph showing dextrocardia.

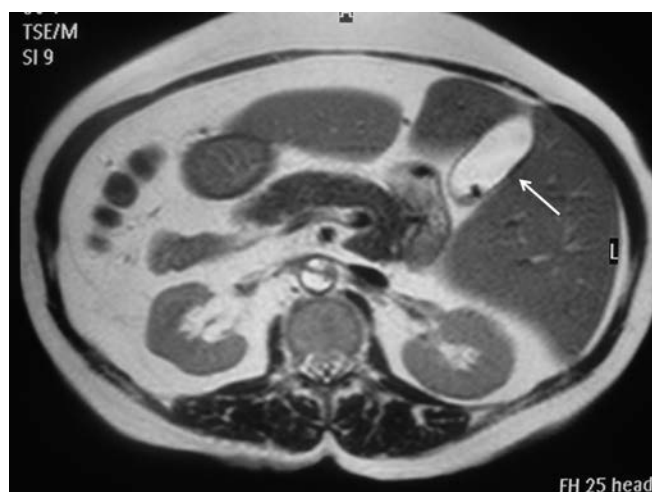

Figure 2. Case 1: MRCP showing visceral SI with multiple gall bladder stones in a left-sided gall bladder (arrow).

bladder (**Figure 2**) with a normal caliber common bile duct without ductal anomalies (**Figure 3**). A diagnosis of acute cholecystitis and SIT was made. After 24 hours of receiving intravenous antibiotics, the patient was taken to the operating room for laparoscopic cholecystectomy. She had an uneventful recovery and was discharged home on the first postoperative day. Pathologic examination of the specimen revealed chronic calcular cholecystitis with cholestrolosis.

Case 2

A 35-year-old Saudi Arabian woman, known to have SIT and bronchial asthma with regular bronchodilator therapy, presented to the surgical clinic with a 4-month history of epigastric pain, especially after fatty meals, radiating to

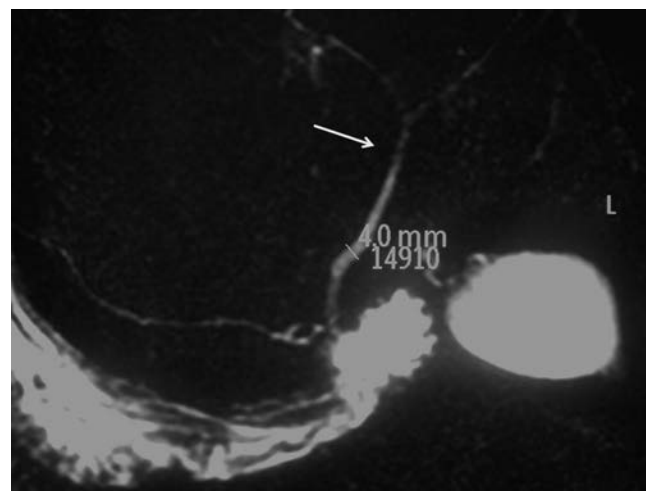


Figure 3. Case 1: MRCP showing normal anatomy of the biliary tree preoperatively, with the common bile duct 4 mm in diameter as shown and the common hepatic duct with its bifurcation (arrow).

the left shoulder and associated with occasional nausea and vomiting. At clinical examination, she was afebrile, not jaundiced, with bilateral wheezy chest sounds, and her abdominal examination was unremarkable. Laboratory findings from complete blood count and liver function tests were within normal ranges.

A chest radiograph showed dextrocardia with bronchiectasis (**Figure 4**). Ultrasonography showed visceral SI with multiple gall stones in a left-sided gall bladder with normal caliber common bile duct. The patient underwent elective laparoscopic cholecystectomy and was maintained postoperatively with chest physiotherapy, postural drainage, antibiotics, bronchodilators, and incentive spirometry. She had an uneventful recovery and was discharged home in good condition on the first postoperative day. Pathologic examination of the specimen revealed chronic calcular cholecystitis.

DISCUSSION

The recognition of SI is important for preventing surgical mishaps that result from the failure to recognize a reversed anatomy or an atypical history. If surgery is planned on the basis of radiographic findings in a patient with SI, the surgeon should pay careful attention to image labeling to avoid errors such as intervention on the incorrect side of the patient.

We report two such cases of SIT with cholelithiasis that were successfully managed by laparoscopic cholecystec-

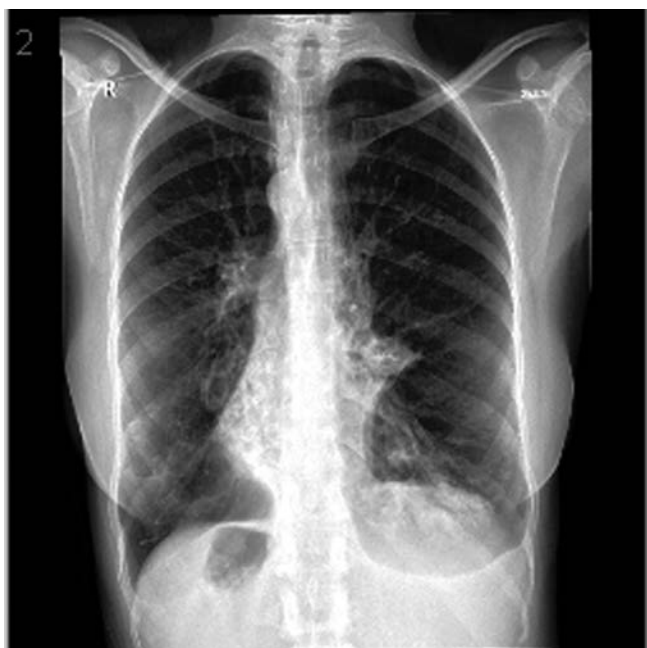

Figure 4. Case 2: Chest radiograph showing dextrocardia with bronchiectasis.

tomy by the same surgeon. However, the approach in the operating room required modification.

A mirror image of the standard laparoscopic cholecystectomy technique was used. The surgeon and the first assistant stood on the right side with the video monitor above the patient's left shoulder. A 4-port technique was used—umbilical (5 mm), medial epigastric (10 mm), and two left lateral subcostal (5 mm) ports placed in the left midclavicular and left anterior axillary lines consequently. The lens used was 45 degrees. After entering the peritoneal cavity and insufflation with carbon dioxide, exploration of the abdominal cavity was undertaken, and the diagnosis of visceral SI was confirmed (**Figure 5**).

The main difficulty encountered was that the primary surgeon, who was right-handed, would have had to cross hands to retract on Hartman's pouch while dissecting Calot's triangle through the epigastric port. We overcame this difficulty by allowing the first assistant to retract on the Hartman's pouch while the primary surgeon dissected Calot's triangle without hindrance using his right hand via the epigastric port. After identification of the cystic duct and cystic artery, clips were applied for each and transected, and the gall bladder was removed from the hepatic bed without difficulty. The remainder of the operation proceeded normally without incident. The total operation time was 38 minutes for the first case and 46 minutes for

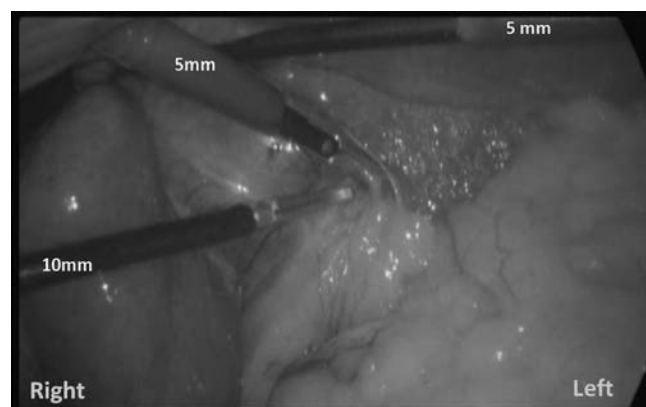


Figure 5. Intraoperative laparoscopic view during cholecystectomy for Case 1 with SI, showing placement of the trocars in the mirror image of the normal setup for cholecystectomy.

the second case. However, a left-handed surgeon has a clear advantage, because of the ability to alternate the performance of dissection maneuvers between the right and left hands.

However, a modified technique has been reported of interchanging the epigastric (5 mm) and left midclavicular line ports (10 mm) with the primary surgeon standing between the legs of the patient to overcome the problem of handedness and crossing the instruments.⁹

Furthermore, in case a difficult dissection of Calot's triangle was encountered, a retrograde ("fundus first") dissection with an application of an ENDOLOOP (Ethicon, Cincinnati, Ohio, USA) ligature to the cystic duct and artery has been described. Although this technique is frequently used in open cholecystectomy, its feasibility in laparoscopic cholecystectomy has not been widely practiced. However, the report has shown that the procedure can be safely carried out laparoscopically in a patient with SI.⁸

Recently, single-incision laparoscopic cholecystectomy was developed to reduce the invasiveness of standard laparoscopy and it began a new era in the minimally invasive approach of performing cholecystectomy. Moreover, reports have shown that single-incision laparoscopic cholecystectomy can be performed safely in SIT, and it may confer an advantage over the orthotopic position for right-handed surgeons.¹⁰

CONCLUSION

Although laparoscopic cholecystectomy in patients with SIT is technically more demanding, it can be performed

safely. Care should be taken to set up the operating theater in the mirror image of the normal setup for cholecystectomy, and right-handed surgeons must modify their technique to adapt to the mirror image anatomy to comfortably and safely carry out the procedure.

References:

1. Sökmen HM, Özdil K, Çalhan T, et al. Situs inversus totalis and secondary biliary cirrhosis: a case report. *Comp Hepatol*. 2011;10:5.
2. Hildebrandt F, Zhou W. Nephronophthisis-associated ciliopathies. *J Am Soc Nephrol*. 2007;18(6):1855–1871.
3. Eisenberg D. Cholecystectomy in situs inversus totalis: a laparoscopic approach. *Int Med Case Rep J*. 2009;2:27–29.
4. Borgaonkar VD, Deshpande SS, Kulkarni VV. Laparoscopic cholecystectomy and appendectomy in situs inversus totalis: a case report and review of literature. *J Minim Access Surg*. 2011;7:242–245.
5. Malatani TS. Laparoscopic cholecystectomy in situs inversus totalis: a case report and a review of literature. *Ann Saudi Med*. 1996;16(4):458–459.
6. Habib Z, Shanafey S, Arvidsson S. Laparoscopic cholecystectomy in situs viscerum inversus totalis. *Ann Saudi Med*. 1998;18(3):247–248.
7. Hamdi J, Abu Hamdan O. Laparoscopic cholecystectomy in situs inversus totalis. *Saudi J Gastroenterol*. 2008;14(1):31–32.
8. Elbeshry T, Ghnnam W. Retrograde (fundus first) laparoscopic cholecystectomy in situs inversus totalis. *Sultan Qaboos Univ Med J*. 2012;12(1):113–115.
9. Patle NM, Tania O, Sasmal PK, Khanna S, Sen B. Laparoscopic cholecystectomy in situs inversus—our experience of 6 cases. *Indian J Surg*. 2010;72(5):391–394.
10. Uludag M, Yetkin G, Kartal A. Single-incision laparoscopic cholecystectomy in situs inversus totalis. *JSLs*. 2011;15:239–243.